

## Mid-Line Linear Fronto-Nasal Osteoma

Jakhar D<sup>1\*</sup> and Kaur P

<sup>1</sup>Department of Dermatology, Sanjay Gandhi Memorial Hospital, New Delhi 110081, India

<sup>2</sup>Department of Dermatology & STD, University college of Medical Sciences & GTBH, Dilshad Garden, New Delhi-110095, India

### Clinical Image

A 40 year old female presented with a linear fronto-nasal growth for the past 10 years. It has been progressively increasing in size. There is no history of trauma in the past and the growth is not associated with any pain, headache, recurrent upper respiratory tract infections and ocular complaints. On examination the growth is hard in consistency and fixed to the underlying structure. The overlying skin was freely mobile. Plain radiograph and CECT confirmed the exact localisation and extension of osteoma with involvement of the frontal sinus. Ophthalmological evaluation including fundoscopy was non-contributory. Patient was counselled and explained various management options. She opted for a conservative approach as it was asymptomatic in nature.

Frontal osteomas can produce neurological and ophthalmological complications. A complete excision is curative in most of cases. Post-operative CSF leak is a major problem.

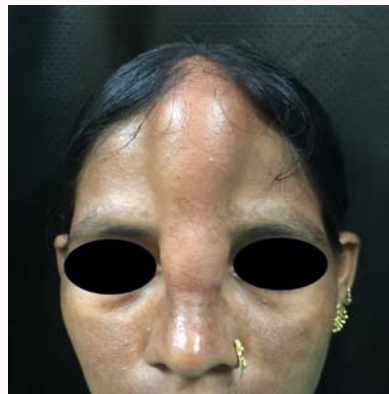


Figure 1:

### OPEN ACCESS

#### \*Correspondence:

Dr. Deepak Jakhar, Department of Dermatology, Sanjay Gandhi Memorial Hospital, H.NO - 82, V.P.O Goyla Khurd, India.

Tel: 91-9654616205

E-mail: dr.deepakjakhar@yahoo.in

Received Date: 08 Dec 2017

Accepted Date: 15 Jan 2018

Published Date: 26 Jan 2018

Citation: Jakhar D, Kaur I. Mid-Line Linear Fronto-Nasal Osteoma. J Dermatolog Forecast. 2018; 1(1): 1004.

Copyright © 2018 Jakhar D. This is an open access article distributed under the Creative Commons Attribution License, which permits unrestricted use, distribution, and reproduction in any medium, provided the original work is properly cited.