

SF Journal of Renal Medicine and Urology

Thrombosis of Renal Vein after RIRS Procedure in Pediatric Patient - A Case Report

Samotyjek J* and Jurkiewicz B

Pediatric Surgery and Urology Department, Center of Postgraduate Medical Education, Poland

Abstract

Recent epidemiological studies have shown that incidence of urolithiasis in pediatric patients is on the rise and has greater increasing incidence in the western world [1-3]. Because of high risk of recurrence children require minimally invasive and effective treatment methods. One of them is Retrograde Intrarenal ureterolithotripsy (RIRS). This technique although commonly used in adults still remains a challenging procedure in pediatric population. Moreover, small cohorts of patients in published studies confirm still insufficient experience in discussed mater. RIRS is safe and effective procedure even for stones in lower pole location, stones up to 30mm, and in children from age of 3 month [4]. However as every procedure RIRS has its complications; intraoperative are ureteral mucosa injury, ureteral or renal pelvic perforation, ureteropelvic or ureterovesical junction injury, and ureter avulsion. Postoperative complications are UTI and fever, post-op hematuria, nausea, vomiting, abdominal pain, voiding disturbance, obstruction after removal of the ureteral catheter, ureteral stricture, and vesicoureteral reflux [5]. None available studies describe renal vein thrombosis. This paper is to present unknown complication after RIRS thrombosis of renal vein.

Keywords: RIRS; Complications; Thrombosis; Children

Case Presentation

A 14 years old girl with bilateral urolithiasis was admitted to Pediatric Surgery and Urology ward for planned RIRS procedure. Patient with Primary Sclerosing Cholangitis and Autoimmune Hepatitis (PSC-AIH overlap syndrome), colitis ulcerosa, with critical stenosis of extra hepatic bile ducts.

In medical history first episode of macroscopic hematuria occurred at the age of six. In ultrasonographic imaging no renal stones were described. In 2014 another hematuria episode occurred this time with abdominal pain and fever. Complex diagnosis was conducted. No urolithiasis was diagnosed but AIH/PSC overlap syndrome was recognized. After four years of conservative treatment patient was qualified of liver transplantation.

In November 2018 UTI with sterile leucocyturia has occurred. In abdominal CTs bilateral urolithiasis was described in right pelvis stone 25x12x8 mm and in left pelvis 19x14x7mm (Figure 1).

Since then, patient remains under constant care of Pediatric Surgery and Urology Clinic. Because of PSC-AIH overlap syndrome and high risk of bleeding choosing the most effective and save treatment method was challenging. In January 2019 RIRS of right kidney after presenting was performed. The procedure was carried out routinely. The only intraoperative problem was bleeding and in consequence poor visibility. During the procedure left ureter was presented. Day after procedure patient required two units of red cells concentrate transfusion because of low hematological parameters. After one month patient was admitted one more time to our Clinic for RISR of left kidney stones in pelvis 19x14x7 mm, in lower calyx 14x6 mm, in upper calyx 7 mm. Before procedure perioperative prophylaxis ciprofloxacin and vitamin K because of Partial Tromboplasmin Time (PTT) 58.4 sec and thrombocytopenia 134,000/ μ l were implemented. RIRS was performed with flexible ureteroscope after placing access sheath. A manual irrigation pump system was used with isotonic fluid at body temperature to avoid hypothermia and hyponatremia. Stones were fragmented using holmium-YAG laser. Postoperative ureteral stent was placed. The procedure time was 69 min. Bleeding during surgery significantly hindered visibility. Even at the beginning while introducing ureteroscope, the ureter and pelvis were full of clots. That is why the average pressure on manual pump was probably higher than used routinely. There were no other exceptions to the

OPEN ACCESS

*Correspondence:

Joanna Samotyjek, Pediatric Surgery and Urology Clinic, Postgraduate Medical Center, Dziekanów Leśny Ul, Marii Konopnickiej 65, Poland.

Tel: +48603281617

E-mail: asiamed@poczta.onet.pl

Received Date: 24 Mar 2020

Accepted Date: 15 Apr 2020

Published Date: 22 Apr 2020

Citation: Samotyjek J, Jurkiewicz B.

Thrombosis of Renal Vein after RIRS Procedure in Pediatric Patient - A Case Report. *SF J Renal Med Urol.* 2020; 1(1): 1001.

Copyright © 2020 Samotyjek J. This is an open access article distributed under the Creative Commons Attribution License, which permits unrestricted use, distribution, and reproduction in any medium, provided the original work is properly cited.

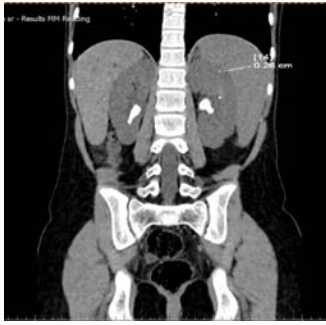


Figure 1: Abdominal CT scan before endourological treatment.

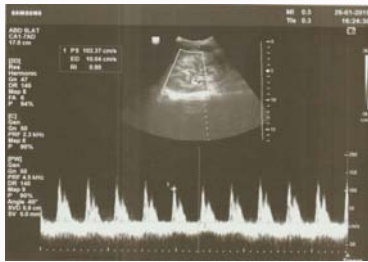


Figure 2: USS scan of left kidney RI = 0.9.

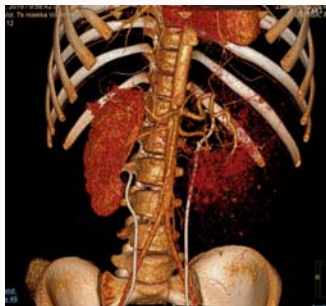

Figure 3: Angio CT after RIRS procedure.

procedure that is commonly performed in our Clinic. On the second day after RIRS the patient was painless, no fever, normal miction. In Ultrasound Scan (US) it was described heterogeneous echogenicity of the cortex of left kidney especially in the upper pole, where clearly worse vascularization and banded hyperechogenic changes were visible. Resistance Index (RI) (RI norm for kidney 0.57-0.70) in left kidney was 0.78 (Figures 2 and 3). It increased on the next day to 0.9. Moreover inflammatory markers increased CRP 86.4 mg/dl and the level of Fibrin Degradation Product (FDP) rapidly increased to 2330 ng/ml. On the 10 day after RIRS procedure a clot 37x13 mm on the border of the inferior vena cava and left renal vein was described in USS. Despite high PTT 47.5 sec, and thrombocytopenia 96,000/ μ l nadroparinum and a total ban on getting up for 10 days was implemented. Reduction of thrombus in the vein has been observed. On the 23rd day after RIRS in USS no signs of clot had been observed. Left kidney with heterogeneous increased echogenicity of the cortex with clearly less cortical vascularization, especially in the upper pole with features of normalization of arterial inflow to the RI level of 0.6 was described. In lower pole of left kidney cluster of stones up to 14 mm and in lower pole of right kidney stone 9 mm were found. However control renoscintigraphy on 24th day after RIRS presented decrease

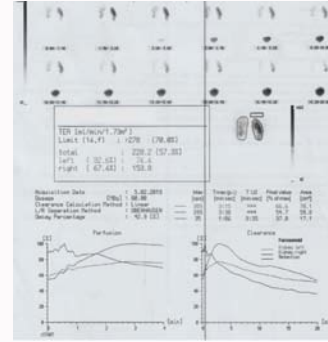


Figure 4: Renoscintigraphy 24 days after left kidney RIRS procedure.

of left kidney function % eRPF LK (effective renal plasma flow of left kidney) 32.6% (Figure 4) In comparison to renoscintigraphy performed 4 months earlier % eRPF = LK 48%, significant decrease of left kidney function occurred. The girl was discharged home on the 25th day after RIRS procedure, after two units of red cells concentrate transfusion, after antibiotal and nadroparinum treatment and with the partial loss of left kidney function. The multidisciplinary team decided to carry out the transplant of liver procedure first and then continue stone removal treatment.

Conclusion

There are no studies presenting this type of complication after RIRS procedure in pediatric population. It is difficult to determine the reason for thrombosis of renal vein in this patient. Because of PSC-AIH overlap syndrome coagulation disorders were expected but rather bleeding (longer PTT, thrombocytopenia) than thrombosis. During the procedure the pressure in pelvis was higher than we normally use, so this could be considered as risk factor. Nadroparinum appeared to be effective and sufficient treatment and after 14 days no signs of thrombus were visible.

Even though we know that RIRS in pediatric population is safe and effective, the small number of patients involved in available literature studies makes our experience insufficient. It is important to be aware of the possibility of thrombosis of renal vein occurrence after RIRS procedure and in consequence loss of kidney function.

References

1. Taylor EN, Stampfer MJ, Curhan GC. Dietary factors and the risk of incident kidney stones in men: new insights after 14 years of follow up. *J Am Soc Nephrol.* 2004; 15: 3225-3232.
2. Tasian GE, Ross ME, Song L, Sas DJ, Keren R, Denburg MR, et al. Annual incidence of nephrolithiasis among children and adults in South Carolina from 1997 to 2012. *Clin J Am Soc Nephrol.* 2016; 11: 488-496.
3. Sas DJ, Husley TC, Shatat IF, Orak JK. Increasing incidence of kidney stones in children evaluated in the emergency department. *J Pediatr.* 2010; 157: 132-137.
4. Ishii H, Griffin S, Somani BK. Flexible Ureteroscopy and lasertripsy (FURSL) for pediatric renal calculi: Results from a systematic review. *J Ped Urol.* 2014; 10: 1020-1025.
5. Chen Y, Deng T, Duan X, Zhu W, ZengG. Percutaneous nephrolithotomy versus retrograde intrarenal surgery for pediatric patients with upper urinary stones: a systematic review and meta-analysis. *Urolithiasis.* 2019; 47: 189-199.