SCIENCEFORECAST
Connecting Research to Drive Scientific Innovation

Research Article
Published: 14 Apr, 2020

SF Journal of Anatomy

Assessment the Effect of Adipose-derived Stem Cells and Phenytoin on Open Cutaneous Wound healing in an Animal Model

Ebrahimzade M[1], Mirdoraghi M[2], Alikarami A[3], Rezaeiyazdi F[1], Rahmati J[4] and Takzaree N[1]*

[1]*Department of Anatomy, School of Medicine, Tehran University of Medical Sciences, Iran*

[2]*Department of Radiology and Radiotherapy, School of Allied Medicine, Tehran University of Medical Sciences, Iran*

[3]*Department of Anatomical Sciences, Faculty of Medicine, Kurdistan University of Medical Sciences, Iran*

[4]*Department of Plastic and Reconstructive Surgery, Razi Hospital, Tehran University of Medical Sciences, Iran*

Abstract

Background: The skin is an integrated organ that provides protective coating against pathogenic factors on the body surface. The purpose of this study was to evaluate the effect of Adipose-derived Stem Cells (ASCs) and phenytoin on open cutaneous wound healing.

Methods: After anesthetizing rats, open skin ulcers were created by bistoury blade. In the treatment groups, the culture medium and ASCs were injected only on the first day of the study. The wound surfaces were evaluated by IMAGEJ software. The cells were enumerated using Immunohistochemistry techniques and IMAGEJ software. The content of collagen and the number of capillaries were determined by Tri-chromosome and H&E staining, respectively.

Results: There was a significant relationship between the number of fibroblasts in the ASCs group and control group on day 4,7 and 14; There were significant relationships between the number of vessels in ASCs, phenytoin, and control groups on day 4,7 and 14; there were significant differences between the number of macrophages in ASCs and control group on day 4,7 and 14 ($P<0.05$).

Conclusion: ASCs accelerate the wound healing process and reduce inflammation; in addition, it increases granulation tissue, epithelialization process, collagen deposition, the number of fibroblasts, and angiogenesis.

Keywords: Adipocyte-derived stem cells; Wound healing; Animal model; Phenytoin

Introduction

The skin is an expansive, integrated organ that protects body surface against environmental and pathogenic factors. Any defect in the integrity of the skin and the formation of injuries can impair the protective functions of the skin and may cause various complications [1]. Increasing the wound healing rate with less side effects is of great importance in medical-related research. Improper and unduly wound healing can lead to infections, physical disabilities, inappropriate appearance and even death in severe cases [2,3]. Wound healing includes four stages; haemostasis, inflammation, proliferation, and remodeling [4]. Hemostasis, the first stage of wound healing, starts at the beginning of the injury and aims to stop the bleeding. At this stage, the body creates a barrier to prevent drainage by operating the emergency repair system, the blood clotting system. During this process, the platelets are activated and accumulated after contacting with collagen. Thrombin, a key enzyme in the hemostasis, forms a fibrin mesh by converting fibrinogen to fibrin [5].

The main purpose of the second phase, known as the inflammation phase, is to destroy bacteria and take away debris by preparing the wound bed for the development of new tissue. In phase 2, a type of white blood cell called a neutrophil enters the wound to kill bacteria and waste. These cells usually peak between 24 and 48 hours after injury, and their count decreases significantly after three days. As neutrophils leave, specialized cells called macrophages enter to remove debris. These cells also accelerate tissue repair by secreting proteins and growth factors that signal immune system cells to come into the wound. This stage often lasts about one week and is often accompanied by swelling, heat, edema and pain [6].

OPEN ACCESS

Correspondence:
Takzaree Nasrin, Department of Anatomy, School of Medicine, Tehran University of Medical Sciences, Tehran, Iran.
E-mail: *takzaree@gmail.com*

Received Date: *24 Mar 2020*
Accepted Date: *09 Apr 2020*
Published Date: *14 Apr 2020*

Citation: *Ebrahimzade M, Mirdoraghi M, Alikarami A, Rezaeiyazdi F, Rahmati J, Takzaree N. Assessment the Effect of Adipose-derived Stem Cells and Phenytoin on Open Cutaneous Wound healing in an Animal Model. SF J Anat. 2020; 3(1): 1009.*

ISSN 2643-7090

Copyright *© 2020 Takzaree N. This is an open access article distributed under the Creative Commons Attribution License, which permits unrestricted use, distribution, and reproduction in any medium, provided the original work is properly cited.*

After clearing the wound, the wound enters the proliferation stage, which focuses on filling and covering the wound. The proliferation phase consists of three stages: filling the wound bed, constriction of the wound border, and epithelialization. At the first stage, the granulation tissue begins to fill the wound bed with the extracellular matrix and collagen. Also, new blood vessels are rebuilt. During the second stage, the wound margins become narrower and shrink the wound surface area. In the epithelialization stage, the epithelial cells move toward the surface and margins of the wound in leapfrog mode until the wound is coated with epithelium [7].

During the remodeling phase, the new tissue gradually obtains flexibility and rigidity. At this stage, the maturation and remodeling of tissue begin, and the elastic strength rises up to 80% of the pre-injured strength. The duration of the maturation phase can last from three weeks to two years [8].

During wound healing, a series of connections are made between different cells, cytokine and extracellular matrix mediators [9]. By stimulating cells and adding some effective components on the wound healing process, the speed and quality of wound healing can be improved [10].

Stem cells are able to divide and renew themselves, as well as to differentiate into many specialized cells [11]. Stem cells remain undifferentiated until they receive signals. But after receiving the signals and having the appropriate environment, such as high telomerase activity and lack of dependence to surface, they can greatly proliferate and differentiate into variety of cells. These features have attracted researchers' attention to discover the mechanisms involved in wound healing process [12,13]. Stem cells can be extracted from umbilical cord, bone marrow, adipose tissue, skin and hair follicles [14]. Adipose stem cells are an ideal source for use in wound healing process due to their ease of extraction, high proliferation *in vitro*, high differentiation and secreting numerous paracrine factors [15,16].

The effect of MSCs on the process of diabetic wound healing was evaluated in animal models, which showed promising results and accelerated wound healing [17]. Besides, the use of adipose-derived pluripotent cells improves wound healing and durability of the wound matrix and enhances angiogenesis [18]. Further research has also shown the effect of adipose stem cells on wound healing through angiogenesis [19].

Therefore, the purpose of this study was to compare the effect of adipose-derived stem cells and phenytoin on wound healing rate based on microscopic, histopathological, and macroscopic findings.

Materials and Methods

Animals and experimental design

60 adult male Wistar rats, 3 to 4 months old and weighing 250-300 g, were opted for this study. The study was approved by Ethical Committee of Tehran University of Medical Sciences (Ethics code: IR.TUMS.MEDICINE.REC.1397.919). The rats were held in standard cage on 12 light/12 dark cycle at 25-30°C. To anesthetize rats, ketamine hydrochloride (50 mg/kg body weight) as the main anesthetic, diazepam (4.5 mg/kg body weight) to relax muscles, and pentazocine (0.4 mg/kg body weight) for pretreatment were intramuscularly injected into animals [20]. Under general anesthesia, we shaved the hair behind the neck of the animals and disinfected with povidone-iodine. For each rat, a square wound of 15x15 mm was created. Surgery day was considered as zero day. Rats were randomly categorized into four groups including control group, phenytoin group (positive control), adipose-derived stem cell group, basal medium group. Each group was divided into five smaller study groups on days 4,7 and 14. Subsequently, the positive control group received 5mg topical phenytoin (ointment 1%) once daily; also for the stem cell recipient group, 106 stem cells at passage 4 using 31-gauge needles were injected into the four points in the periphery of each wound [21].

Detachment and culture of Adipose Stem Cells (ASCs)

ASCs were taken out from the supra epididymis zone of animals, subsequently blood and the connective tissues were removed, and the fragmented adipose tissues were incubated for 40 minutes at 37°C, then the tissues were exposed to type 1 collagenase enzyme. Afterwards, the solution was centrifuged at 2500 rpm for 5 minutes at 4°C; and the cells were conveyed to DMEM, 15% FBS, 100 IU/ml penicillin and 100 μg/ml streptomycin. Then, the solution was incubated at 37°C, 5% CO_2 and 9% moisture [22].

Differentiation of MSCs into adipocytes and bone marrow

To determine the pluripotency of cells isolated from adipose tissues by evaluating the differentiation potential of the mesodermal lipid and bone, the cells were first cultured; once their density was about 70-80%, the media was replaced by bone differentiation media (dexamethasone, indometacin DMEM, 10% FBS, L-ascorbic-acid2-phosphate); and lipid differentiation media (B-glycerol phosphate DMEM, 10% FBS, L-Ascorbic acid 2-phosphate). 3 weeks later, the differentiated bone and fat tissues were stained with alizarin red and oil red, respectively.

Identification of surface indicators by flow cytometry technique

The mesenchymal status of the isolated cells, and non-contamination of these cells with blood cells were examined by flow cytometry. To endorse the originality of ASCs, we investigated the surface markers of CD44 and CD34 adipocytes [23,24].

Cell injection: After creating wound on the dermis, 106 passage stem cells 4 were injected with a 31G insulin syringe into 4 corners on the periphery of each wound [25].

Macroscopic examination of wounds

The area of wound surface was assessed on days 1,4,7,10 and 14, using IMAGEJ software. Furthermore, the wound healing rate was estimated based on the following formula [26]:

Wound Healing Rate = (Wound surface on the first day-wound surface on the (X) day/ Wound surface on the first day) x 100

X is the wound surface measured on given day.

Microscopic examination of wounds

The tissues were fixed and passaged, then 6-micron pieces were removed from wound and its contiguous skin. The sections were stained with haematoxylin-eosin and Masson's trichrome method. To count cells of bed wound, quantitative and qualitative examinations were accomplished using Olympus CX31 Microscope (Olympus, Tokyo, Japan), objective lens, and J Image software.

Immunohistochemistry

The number of fibroblast cells in the wound bed was counted using the Vimentin antibody. To carry out the immunohistochemical technique, the tissues were fixed and cut after dehydrating and

Table 1: Mean ± SD wound healing rate at different times.

Time	Group	Mean	Std. Deviation
Day 4	Control	5.18	0.92
	Base Medium	6.37	1.11
	ADSCs	22.66	0.76
	Control positive (phenytoin 1%)	13.03	0.92
Day 7	Control	18.66	1.60
	Base Medium	18.96	1.68
	ADSCs	36.29	0.51
	Control + (phenytoin 1%)	21.333	0.88
Day 10	Control	30.37	0.92
	Base Medium	30.66	1.33
	ADSCs	40.44	0.44
	Control positive (phenytoin 1%)	33.33	0.44
Day 14	Control	51.70	2.44
	Base Medium	50.81	1.68
	ADSCs	99.85	0.25
	Control positive (phenytoin 1%)	62.07	0.25

coating with paraffin. The antibodies were heated at 95°C for 95 minutes. Subsequently, they were washed with oxygenated water and PBS buffer. Then, they were stained with H&E (Hematoxylin and Eosin) staining [27].

Tri-chromosome staining: The identification of blue collagen filaments is the basis of tri-chromosome staining. In skin-related tissue incisions, the creatinine amount within the cytoplasm of epithelial cells is also observed in this type of red staining.

H&E (Hematoxylin and Eosin) staining: Hematoxylin-eosin staining was applied to examine the cell, which allows the nuclei and cytoplasm to turn blue and pink.

Statistical analysis

The normality of data was appraised by Kolmogorov-Smirnov test in SPSS software version 20, and analysis of variance (ANOVA) was used to realize any significant relationship between various groups ($p<0.05$).

Results and Discussion

Table 1 demonstrates Mean ± SD wound healing rate on day 4,7,10,14. There was a significant relationship between wound healing rates in the ASCs group and Phenytoin group ($p<0.01$) (Figure 1 and Diagram 1). There was a significant relationship between the number of fibroblasts in the ASCs group and control group on day 4,7 and 14 ($P<0.001$) (Diagram 7); also there was a significant relationship between the number of fibroblasts in the ASCs group and phenytoin group on day 7 and 14 ($P<0.01$) (Diagram 7). There were significant relationships between the number of vessels in the groups of ASCs, phenytoin group, and control group on day 4,7 and 14 ($P<0.01$) (Diagram 9). Mean granulation rate, mean reepithelialization rate, mean inflammation rate, and collagen level were evaluated on day 14 in all groups (Figure 2, Diagram 2-6); there were significant relationships between measured factors in ASCs group , and control group on day 14 (Diagram 2-6). There were significant differences between the number of macrophages in ASCs and control group on day 4,7 and 14 ($P<0.05$) (Diagram 8).

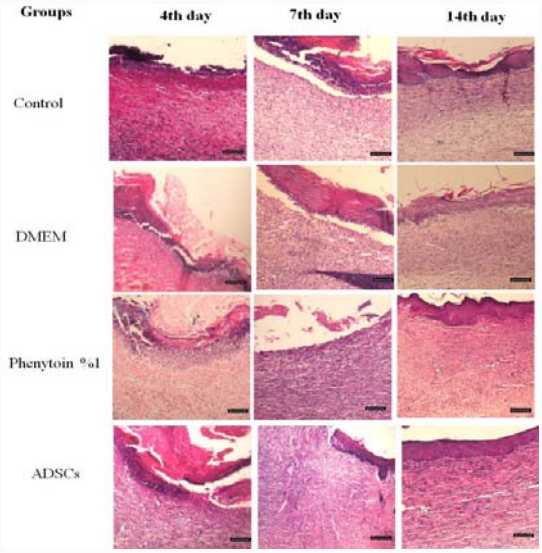

Figure 1: Microscopic view of open cutaneous wounds in control group and experimental groups. 4th day, inflammation is the major phenomenon in wound bed. 7th day, epithelialization, mature, collagen fibers and granulation tissue are seen in neotissues. 14th day, complete epithelialization, a large amount of collagen fibers and granulation tissue are observed. (Staining, H&E ˙10) (Scale bar = 100).

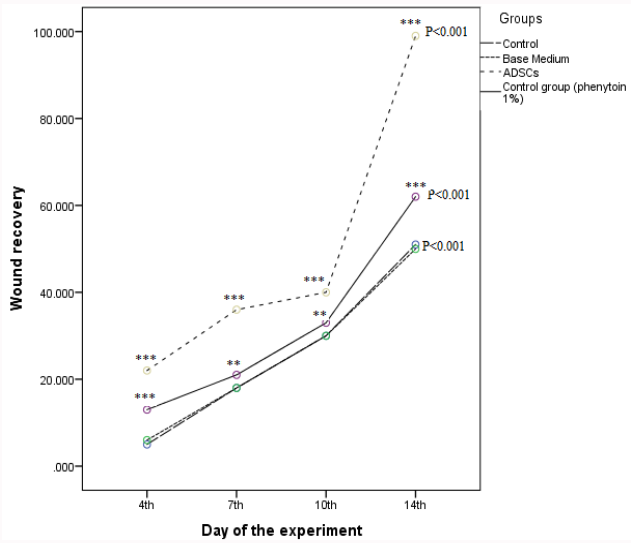

Diagram 1: Comparison of the wound healing rate in 10 areas with H&E staining on the 4th,7th,10th and 14th day in different groups.

Reducing the time wound takes to heal is one of the most important principles in medicine and surgery. Accelerating the wound healing process, by stimulating an external agent, can reduce treatment costs and improve health [28]. To date, various studies have been conducted on wound healing that has led to the discovery of many natural and chemical agents that improve the healing process [29-31]. Stem cells are highly reproducible and can be transformed into other cell types. By secreting a variety of growth factors and signaling function, they play a vital role in the formation of organs and tissues both in fetus and in adults. Within a healthy or damaged organ, pluripotent stem cells are able to rapidly transform into a variety of cells [32,33]. Based on these special features of stem cells, regenerative medicine has received particular attention.

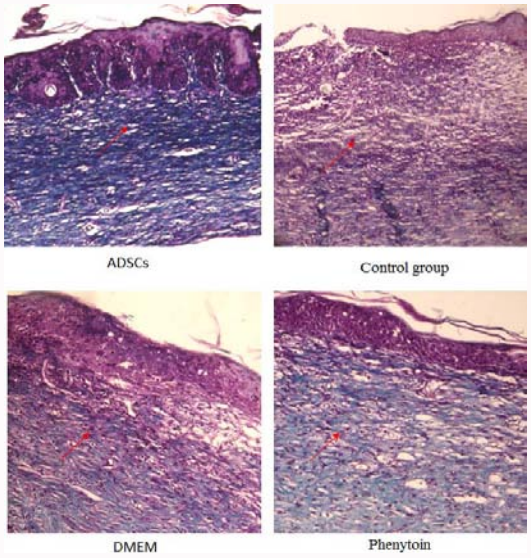

Figure 2: Microscopic view of open cutaneous wounds: Control group, the number of collagen fibers are fewer than the experimental groups in this picture; Experimental groups, the number of collagen fibers are greater than the control group in this picture (specific staining, Masson's trichrome ˙20).

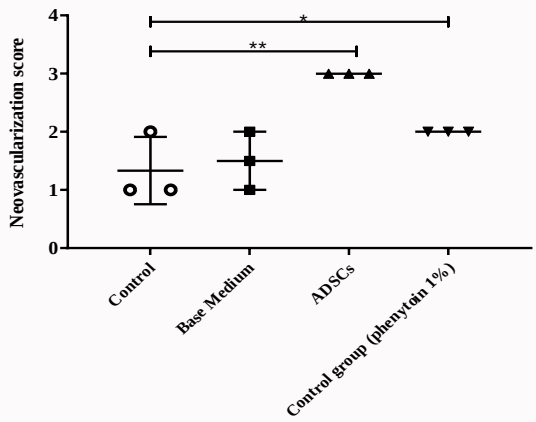

Diagram 2: Histopathology evaluation of vascular bundle rate on day 14 in all groups based on mean of 10 areas in wound by magnification ×400.

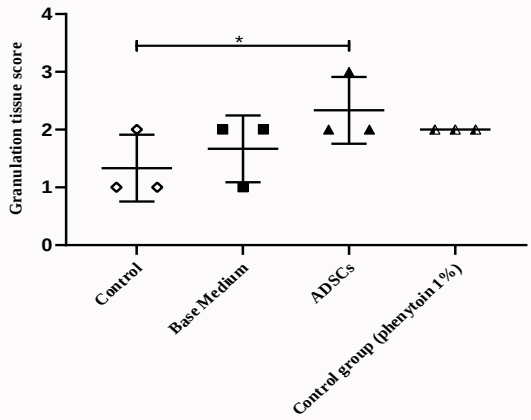

Diagram 3: Histopathology evaluation of granulation rate on day 14 in all groups based on mean of 10 areas in wound by magnification ×400.

The result of a study showed that the angiogenesis rate and the number of fibroblasts in treated groups with stem cells had increased,

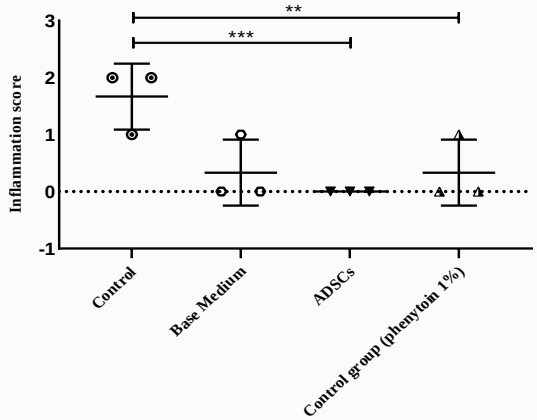

Diagram 4: Histopathology evaluation of inflammation rate on day 14 in all groups based on mean of 10 areas in wound by magnification ×400.

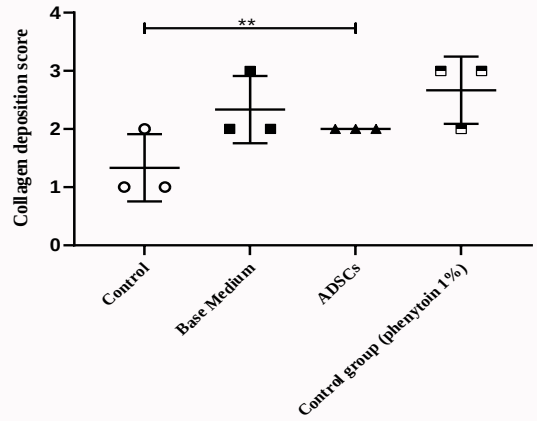

Diagram 5: Histopathology evaluation of collagen level on day 14 in all groups based on mean of 10 areas in wound by magnification ×400.

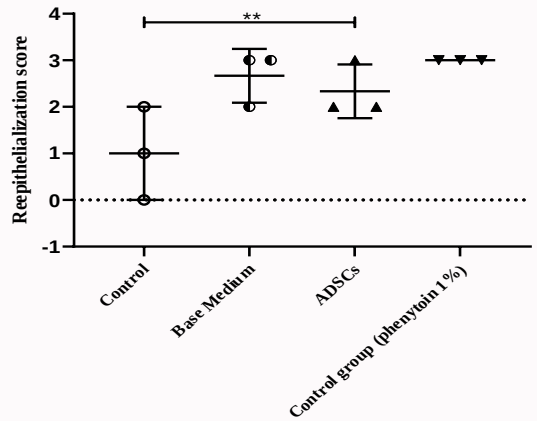

Diagram 6: Histopathology evaluation of reepithelialization rate on day 14 in all groups based on mean of areas in wound by magnification ×400.

and these findings are in line with our study [34]. In our study in ASCs group, the levels of fibroblasts, the essential part for cellular matrix formation and repair, on days 4,7, and 14 had augmented that can be a fundamental agent in accelerating wound healing (Diagram 7). Kyung Y *et al*. concluded that stem cells increase growth factors, promote wound healing, and increase granulation tissues [35].

In addition, another study revealed that wound area in ASCs group was significantly different from other groups; and there wound

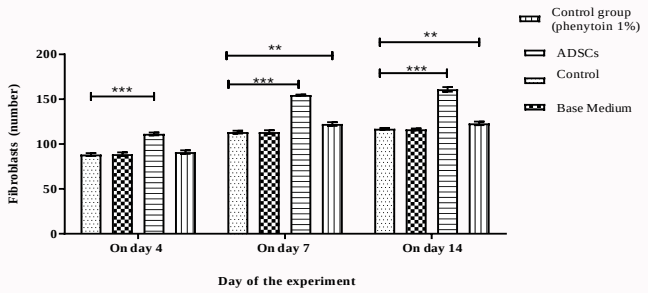

Diagram 7: Comparison of the number of fibroblasts in 10 areas with H&E staining on the 4th,7th,14th day in different groups.

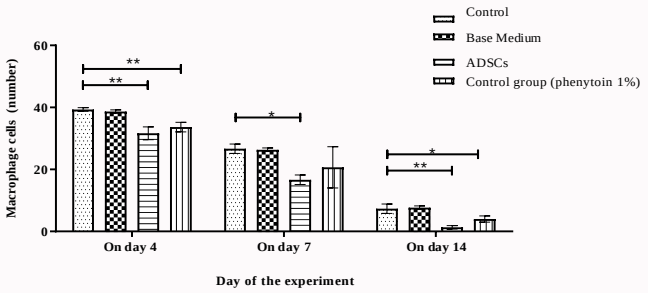

Diagram 8: Comparison of the number of macrophages in 10 areas with H&E staining on the 4th,7th,14th day in different groups.

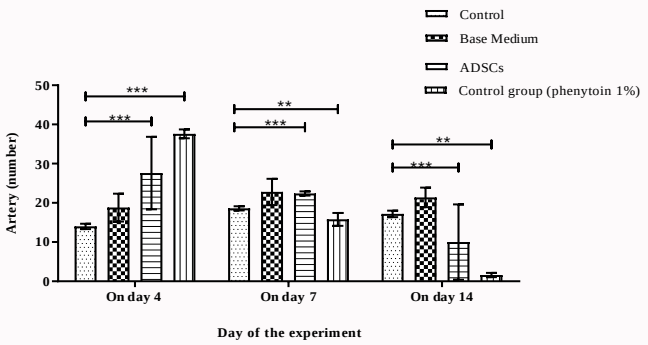

Diagram 9: Comparison of the number of vessels in 10 areas with H&E staining on the 4th,7th,14th day in different groups.

surface area was decreased, especially at day 14. The reason for this phenomenon is that wound needs to be nourished by the blood vessels of adjacent connective tissues [36]. In our study, there was seen a rise in blood vessels in ASCs group as well as in the phenytoin group, indicating a better nutrition of new epithelial cells and a better quality of wound healing in these groups than other groups.

The results of our research are in alignment with the findings of other studies, which indicate a positive effect of ASCs on the healing process through the application of growth factors, angiogenesis and proliferation of regenerative cells [37-39]. We also observed high levels of blood vessels and low levels of inflammation in ASCs group (Diagram 4,9).

It is worthwhile to mention that Platelet Rich Plasma (PRP) and Autologous Fat Grafting can accelerate the wound healing process. Their mechanism is that a combination of these factors like Adipose-derived Stem Cells (ASCs), can increases growth factors such as Vascular Endothelial Growth Factor (VEGF), platelet factors and transforming growth factor. They also can regulate angiogenesis and decrease wound surface area and also have antibacterial effects but Adipose-derived Stem Cells (ASCs) increase the process of vascularization and does not have antibacterial effects [40-42].

Finally, the results of conducted studies in this field indicate the positive effect of ASCs on wound healing. The therapeutic effect, the quality and speed of ASCs on wound healing were promising, and ASCs improved wound healing.

Conclusion

The results of this study demonstrated that wound healing rate, granulation tissues, epithelialization process, collagen deposition, the number of fibroblasts, angiogenesis in ASCs group increased; moreover, inflammation rate decreased. These finding suggests that ASCs can be used in wound healing in the future as they accelerate the wound healing process by increasing or decreasing several parameters.

Suggestion

The authors of the manuscript suggest that more research needs to scrutinize the histopathological effects of intravenous ASCs on animal model.

Acknowledgment

This work was supported by Tehran University of Medical Sciences.

References

1. Dulmovits BM, Herman IM. Microvascular remodeling and wound healing: a role for pericytes. Int J Biochem Cell Biol. 2012; 44: 1800-1812.
2. Sanna-Maria K, Ritva H, Gullberg D, Kaisa T, Taina P. Toward understanding scarless skin wound healing and pathological scarring. F1000Research. 2019.
3. Larouche J, Sheoran S, Maruyama K, Martino MM. Immune regulation of skin wound healing: mechanisms and novel therapeutic targets. Adv Wound Care. 2018; 7: 209-231.
4. Netam AK, Prasad J, Satapathy T. A Review on Ethnopharmacological approaches to Wound Healing and Curative Progression. Res J Pharmacol Pharmacodyn. 2019; 11: 37-45.
5. Hosgood G. Stages of wound healing and their clinical relevance. Vet Clin North Am Small Anim Pract. 2006; 36: 667-685.
6. Beldon P. Basic science of wound healing. Surgery. 2010; 28: 409-412.
7. Enoch S, Leaper DJ. Basic science of wound healing. Surgery. 2008.
8. Velnar T, Bailey T, Smrkolj V. The wound healing process: an overview of the cellular and molecular mechanisms. J Int Med Res. 2009; 37: 1528-1542.
9. Ferroni L, Gardin C, Paola LD, Campo G, Cimaglia P, Bellin G, et al. Characterization of dermal stem cells of diabetic patients. Cells. 2019; 8: 729.
10. Gould L, Abadir P, Brem H, Carter M, Conner-Kerr T, Davidson J, et al. Chronic wound repair and healing in older adults: current status and future research. J Am Geriatr Soc. 2015; 63: 427-438.
11. Roubelakis MG. Introduction to Stem Cell Principles and Biology. Digestive System Diseases. 2019.
12. Crosnier C, Stamataki D, Lewis J. Organizing cell renewal in the intestine: stem cells, signals and combinatorial control. Nature Rev Genet. 2006; 7: 349.
13. Dalerba P, Diehn M, Weissman IL, Clarke MF. 7-Stem Cells, Cell Differentiation, and Cancer. Abeloff's Clinical Oncology. 2020.

14. Mahmood R, Shaukat M, Choudhery MS. Biological properties of mesenchymal stem cells derived from adipose tissue, umbilical cord tissue and bone marrow. CTE. 2018; 2: 78-90.

15. Wankhade UD, Shen M, Kolhe R, Fulzele S. Advances in adipose-derived stem cells isolation, characterization, and application in regenerative tissue engineering. Stem Cells Int. 2016.

16. Bertozzi N, Simonacci F, Grieco MP, Grignaffini E, Raposio E. The biological and clinical basis for the use of adipose-derived stem cells in the field of wound healing. Ann Med Surg. 2017; 20: 41-48.

17. Maharlooei MK, Bagheri M, Solhjou Z, Jahromi BM, Akrami M, Rohani L, et al. Adipose tissue derived mesenchymal stem cell (AD-MSC) promotes skin wound healing in diabetic rats. Diabetes Res Clin Pract. 2011; 93: 228-234.

18. Lin YC, Grahovac T, Oh SJ, Ieraci M, Rubin JP, Marra KG. Evaluation of a multi-layer adipose-derived stem cell sheet in a full-thickness wound healing model. Acta Biomater. 2013; 9: 5243-5250.

19. Zografou A, Tsigris C, Papadopoulos O, Kavantzas N, Patsouris E, Donta I, et al. Improvement of skin-graft survival after autologous transplantation of adipose-derived stem cells in rats. J Plast Reconstr Aesthet Surg. 2011; 64:1647-1656.

20. Takzare N, Hosseini M, Hasanzadeh G, Mortazavi H, Takzare A, Habibi P. Influence of Aloe Vera gel on dermal wound healing process in rat. Toxicology Mechanisms and Methods. 2009; 19: 73-77.

21. Wang X, Ge J, Tredget EE, Wu Y. The mouse excisional wound splinting model, including applications for stem cell transplantation. Nat Protoc. 2013; 8: 302-309.

22. Zuk PA, Zhu MIN, Mizuno H, Huang J, Futrell JW, Katz AJ, et al. Multilineage cells from human adipose tissue: implications for cell-based therapies. Tissue Eng. 2001; 7: 211-228.

23. Kenarkoohi A, Soleimani M, Bamdad T, Soleimanjahi H, Estiri H, Razavi-Nikoo MH. Efficient lentiviral transduction of adipose tissue-derived mouse mesenchymal stem cells and assessment of their penetration in female mice cervical tumor model. Iran J Cancer Prev. 2014; 7: 225-231.

24. Gronthos S. A Roadmap to Non-Hematopoietic Stem Cell-based Therapeutics. Elsevier. 2019.

25. Nadri S, Soleimani M. Isolation murine mesenchymal stem cells by positive selection. *In Vitro* Cel Dev Biol Anim. 2007; 43: 276-282.

26. Tawfeek HM, Abou-Taleb DAE, Badary DM, Ibrahim M, Abdellatif AAH. Pharmaceutical, clinical, and immunohistochemical studies of metformin hydrochloride topical hydrogel for wound healing application. Arch Dermatol Res. 2019; 312: 113-121.

27. Goodpaster T, Legesse-Miller A, Hameed MR, Aisner SC, Randolph-Habecker J, Coller HA. An immunohistochemical method for identifying fibroblasts in formalin-fixed, paraffin-embedded tissue. J Histochem Cytochem. 2008; 56: 347-358.

28. Anlas C, Bakirel T, Ustun-Alkan F, Celik B, Baran MY, Ustuner O, et al. *In vitro* evaluation of the therapeutic potential of Anatolian kermes oak (Quercus coccifera L.) as an alternative wound healing agent. Industrial Crops and Products. 2019; 137: 24-32.

29. Johnson ZI, Mahoney C, Heo J, Frankel E, Julian DR, Yates CC. Fibrosis in Disease. Springer. 2019.

30. Molan PC, Rhodes T. Honey: a biologic wound dressing. Wounds. 2015; 27: 141-151.

31. Mokhtari S, Sanati I, Abdolahy S, Hosseini Z. Evaluation of the effect of honey on the healing of tooth extraction wounds in 4-to 9-year-old children. Niger J Clin Pract. 2019; 22: 1328-1334.

32. Sijacic P, Bajic M, McKinney EC, Meagher RB, Deal RB. Changes in chromatin accessibility between Arabidopsis stem cells and mesophyll cells illuminate cell type-specific transcription factor networks. Plant J. 2018; 94: 215-231.

33. El Maghraby GM, Barry BW, Williams AC. Liposomes and skin: from drug delivery to model membranes. Eur J Pharm Sci. 2008; 34: 203-222.

34. Yu J, Wang M-Y, Tai H-C, Cheng N-C. Cell sheet composed of adipose-derived stem cells demonstrates enhanced skin wound healing with reduced scar formation. Acta Biomater. 2018; 77: 191-200.

35. Na YK, Ban J-J, Lee M, Im W, Kim M. Wound healing potential of adipose tissue stem cell extract. Biochem Biophys Res Commun. 2017; 485: 30-34.

36. Balaji S, Watson CL, Ranjan R, King A, Bollyky PL, Keswani SG. Chemokine involvement in fetal and adult wound healing. Adv Wound Care. 2015; 4: 660-672.

37. Kilroy GE, Foster SJ, Wu X, Ruiz J, Sherwood S, Heifetz A, et al. Cytokine profile of human adipose-derived stem cells: Expression of angiogenic, hematopoietic, and pro-inflammatory factors. J Cell Physiol. 2007; 212: 702-709.

38. J Salgado A, L Reis R, Sousa N, M Gimble J. Adipose tissue derived stem cells secretome: soluble factors and their roles in regenerative medicine. Curr Stem Cell Res Ther. 2010; 5: 103-110.

39. Takzaree N, Hadjiakhondi A, Hassanzadeh G, Rouini MR, Manayi A, Zolbin MM. Transforming growth factor-β (TGF-β) activation in cutaneous wounds after topical application of aloe vera gel. Can J Physiol Pharmacol. 2016; 94: 1285-1290.

40. Tobita M, Tajima S, Mizuno H. Adipose tissue-derived mesenchymal stem cells and platelet-rich plasma: stem cell transplantation methods that enhance stemness. Stem Cell Res Ther. 2015; 6: 215.

41. Gentile P, Orlandi A, Scioli MG, Di Pasquali C, Bocchini I, Curcio CB, et al. A comparative translational study: The combined use of enhanced stromal vascular fraction and platelet-rich plasma improves fat grafting maintenance in breast reconstruction. Stem Cell Transl Med. 2012; 1: 341-351.

42. Sadati KS, Corrado AC, Alexander RW. Platelet-rich plasma (PRP) utilized to promote greater graft volume retention in autologous fat grafting. The American Journal of Cosmetic Surgery. 2006; 23: 203-211.