SCIENCEFORECAST
Connecting Research to Drive Scientific Innovation

Case Report
Published: 08 Jun, 2018

SF Journal of Clinical Case Reports

Cryptococcus Neoformans Meningoencephalitis in an Immunocompetent Patient Complicated by Ogilvie's Syndrome

Davis BJ*, Manninen ES, Mody RM, Scully SE and Sherwood JE

William Beaumont Army Medical Center, 5005 Piedras Ave. El Paso, TX 79920, USA

Abstract

Maintaining a high index of suspicion for atypical infectious causes of meningoencephalitis in immunocompetent patients is critical to rapidly diagnosing and treating potentially life-threatening diseases. We describe the case of a 66-year-old HIV negative male with no known immune compromising conditions found to have cryptococcal meningoencephalitis following a precipitous decline in functional status and awareness. Combination liposomal amphotericin and flucytosine were initiated although his treatment course was complicated by the development of medication-induced electrolyte abnormalities and Ogilvie's syndrome. Offending induction medications were discontinued in concert with correction of underlying electrolyte abnormalities. The patient additionally required treatment with neostigmine to correct the pseudo-obstruction although colonic decompression was not required. His neurological status continued to improve after transition to prolonged oral fluconazole. This case warrants reporting due to the patient's lack of traditional risk factors for cryptococcal meningoencephalitis and the relatively novel gastrointestinal side effects of treatment.

Keywords: Cryptococcus; Immunocompetent; Amphotericin; Flucytosine; Ogilvie's syndrome

Case Presentation

A 66-year-old male was brought to the emergency department by his family after becoming disoriented and unable to follow commands. His family noted a sudden change from baseline characterized by bizarre behavior, agitation, and visual hallucinations. At the time of admission, the patient was unable to understand or communicate with his treatment team. The patient had previously demonstrated stable neurologic baseline following a middle cerebral artery cerebrovascular accident (CVA) eight months prior. Review of systems through discussion with the patient's family was notable for anosmia, altered taste, diminished appetite, and a 40lb unintentional weight loss over a several month period.

The patient's surgical history included several bowel resections following an acute bowel obstruction in the early 1990's. He underwent colonoscopy with no abnormal findings two months prior to admission. The patient had no personal history of recurrent infections or family history of immune compromising conditions. The patient's active medications included only clopidogrel, aspirin, and atorvastatin which were all started following his CVA.

The patient was a military veteran with a 60 pack-year smoking history but no history of illicit drug use or alcohol abuse. He had no recent overseas travel, camping or hiking, animal or insect bites, unusual food exposures, fresh water exposures, or known high risk sexual activity. In retrospect, the patient did recall indirect exposure to birds through yard work and while golfing.

In the emergency department, the patient was afebrile and hemodynamically stable but confused and unresponsive to questions. No focal nor lateralizing neurological defects were appreciated on examination. Cardiac, pulmonary, abdominal, and skin exams were all unremarkable. Initial laboratory evaluation was benign. He had no evidence of leukocytosis, anemia, thrombocytopenia, electrolyte abnormalities, or metabolic derangements as contributors to his acute decline in mental status. Blood alcohol, salicylate, and acetaminophen levels were undetectable. Computed tomography (CT) of the head without contrast revealed no acute intracranial findings.

The patient was admitted for management. An EEG demonstrated epileptiform activity involving the left central and centrotemporal regions (Figure 1). MRI of the brain with and without

OPEN ACCESS

Correspondence:
Bryon J. Davis, William Beaumont Army Medical Center, 5005 Piedras Ave. El Paso, TX 79920, USA.
Tel: *915-479-9768*
E-mail: *bryon.j.davis2.mil@mail.mil*

Received Date: *17 Apr 2018*
Accepted Date: *04 Jun 2018*
Published Date: *08 Jun 2018*

Citation: *Davis BJ, Manninen ES, Mody RM, Scully SE, Sherwood JE. Cryptococcus Neoformans Meningoencephalitis in an Immunocompetent Patient Complicated by Ogilvie's Syndrome. SF J Clin Case Rep. 2018; 1(1): 1007.*

ISSN 2643-8194

Copyright *© 2018 Davis BJ. This is an open access article distributed under the Creative Commons Attribution License, which permits unrestricted use, distribution, and reproduction in any medium, provided the original work is properly cited.*

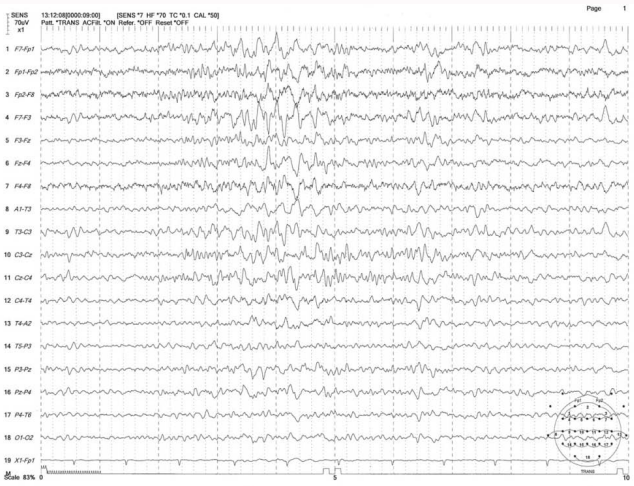

Figure 1: Electroencephalogram demonstrating profound epileptiform activity with classic spike and wave morphology.

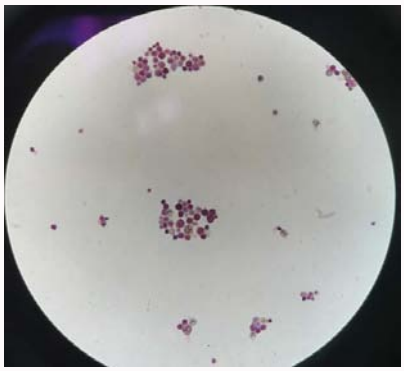

Figure 2: Gram stain of cerebrospinal fluid demonstrating yeast consistent with Crytptococcus neoformans.

contrast revealed no evidence of acute infarct, hemorrhage, or lesions.

Lumbar puncture revealed glucose 21mg/dL, protein 124.27mg/dL, and white blood cells 43 per hpf (9% neutrophils and 95% lymphocytes). Empiric acyclovir and ampicillin were initiated and the primary team consulted the Infectious Disease service. Multiple viral, fungal, and bacterial panels from cerebrospinal fluid and serum were obtained. The patient tested negative for coccidoidomycosis, *T. pallidum, T. whippelli, Brucella*, and West Nile virus by serologic testing. Spinal fluid studies also returned negative for West Nile virus, herpes simplex, varicella zoster, and enterovirus via PCR. The patient was found to be HIV negative and CD4/CD8 cell counts were normal. Cryptococcal antigen via latex agglutination (Remel™) was positive with a titer of 1:4. Spinal fluid cultures eventually grew *Cryptococcus neoformans* (Figure 2). Acyclovir and ampicillin were discontinued. The patient was started on liposomal amphotericin 3mg/kg intravenously daily and flucytosine 25mg/kg orally every six hours.

During the course of his admission, the patient developed right sided anisocoria which prompted serial lumbar punctures. No opening pressure was obtained during his initial diagnostic lumbar puncture, although repeat lumbar puncture revealed an opening pressure of 21cm/H20. The patient ultimately received five lumbar punctures during his hospitalization with gradual improvement in opening pressure to 15.5cmH20. His anisocoria improved and more

Figure 3: Computed tomography image of colonic pseudo-obstruction (Ogilvie's syndrome). Dilated small bowel (arrow) and large bowel are apparent.

invasive shunting procedures were not required.

With these interventions, the patient experienced gradual improvement in mentation and eventually regained baseline awareness and orientation. His anosmia and altered taste improved within a few days of antifungal administration. He was eventually deemed appropriate for discharge with continued outpatient infusions of amphotericin and oral flucytosine. The initial treatment plan was to provide four total weeks of parenteral therapy followed by an eventual transition to oral fluconazole.

Seven days after discharge on his outpatient infusion protocol, the patient returned to the hospital with new complaints of non-bloody diarrhea, nausea with emesis, and abdominal pain with distension. Repeat laboratory evaluation was notable for new hypokalemia at 2.5mmol/L and hypomagnesemia at 1.0mg/dL. Abdominal CT with oral contrast demonstrated diffuse dilation of both the small and large bowel concerning for enterocolitisand poor transit of oral contrast concerning for obstruction (Figure 3). *Clostridium difficile* and other common gastrointestinal pathogens were ruled out using molecular diagnostics. Due to concerns regarding medication-induced colitis and acute colonic pseudo-obstruction (Ogilvie's syndrome) the patient's liposomal amphotericin and flucytosine were discontinued. The patient was transitioned to oral fluconazole 400mg by mouth daily and the patient's metabolic derangements were corrected with supportive care. Gastroenterology was consulted and the patient was treated with a single infusion of neostigmine 2mg over 60 minutes. With these interventions, he experienced gradual improvement of abdominal pain, bowel motility, and oral intake. He remains on a prolonged course of oral fluconazole as an outpatient with ongoing weight gain and no relapsing symptoms at the time of this report.

Discussion/Conclusion

The classically opportunistic *Cryptococcus neoformans* is encapsulated yeast that produces a variety of clinical syndromes across a broad spectrum of patient populations; including meningoencephalitis in patients without identifiable immunodeficiency. The disease can carry upto 20% three-month mortality in patients with acute meningoencephalitis [1]. Although *Cryptococcus neoformans* is the most common cause of fungal meningitis worldwide, before the advent of HIV/AIDS a scant three hundred cases comprised the entire historical cohort [2]. The increased prominence of cryptococcal infection in modern medical practice stems in large part from its close association with immune

compromising conditions. There are now approximately 1 million new cases yearly, mostly in countries with high burdens of HIV and limited medical resources [3]. Extrapulmonary cryptococcal infection represents the fourth most common AIDS defining illness in patients who test positive for HIV [4].

Cryptococcal infections have been reported in immunocompetent patients though, most notably novel species such as *Cryptococcus gatti* or *Cryptococcus neoformans var. grubii*. Originally considered to be confined to Australia and other subtropical regions, cases in the temperate Pacific Northwest region of North America indicate broader potential climates for these pathogens [5-7]. Immunocompetent patients may also become infected with *Cryptococcus neoformans*, which is ubiquitous and found in the droppings of several mammals and birds. Cryptococcal infections begin with inhalation and spread to the central nervous system hematogenously, often without clinical evidence of respiratory infection [8-10]. Although our patient's profound weight loss could have resulted in a relative immune deficiency, his marked improvement in anosmia and taste after initiation of antifungals suggest he may have been suffering from a relatively indolent cryptococcal infection.

Radiographic findings in patients with cryptococcus vary significantly. Some immunocompetent hosts mount a vigorous immune response which leads to enhancement and increased vascular permeability [11]. Imaging can revealcystic or nodular cerebral lesions or be relatively normal as was the case with our patient. Multimodal investigation including lumbar puncture, spinal fluid antigen testing and culture are necessary to adequately detect cryptococcal disease [12,13].

Recommended treatment regimens include amphotericin B and flucytosine for up to a 4 week induction phase in non-HIV infected individuals and transplant recipients. Fluconazole consolidation is typically provided for 8 weeks before reducing the dose to a maintenance regimen for 6-12 months. In patients who develop elevated intracranial pressure resistant to management by serial lumbar puncture a VP shunt may be appropriate [14]. Our patient improved with serial lumbar puncture and required no additional procedures to reduce intracranial pressure.

Combination therapy with amphotericin and flucytosine can have serious adverse effects. Amphotericin is notably nephrotoxic and is implicated in myriad well described metabolic derangements [15,16]. As such, amphotericin undoubtedly contributed to our patient's electrolyte abnormalities and played a role in the development of Ogilvie's syndrome. We also have suspicion that the enterocolitis noted on imaging could have been related to flucytosine, which acts by competing with uracil and interferes with RNA and protein synthesis. Rare but serious colitis has been described in two other patients receiving this agent [17,18]. Colonic pseudo-obstruction has additionally been associated with multiple additional risk factors present in our case to include altered anatomy, systemic infection, and neurologic disease [19]. Our case highlights the potential for severe gastrointestinal side effects due to cryptococcal treatment.

Our patient's clinical condition improved once induction agents were discontinued, electrolytes were replete, and targeted therapy for Ogilvie's was provided. Fluconazole, voriconazole and posaconazole are all suggested by the Infectious Disease Society of America as potential salvage regimens in patients experiencing relapse or persistent symptoms [14]. Our patient was transitioned to long-term oral fluconazole with excellent ongoing clinical response. He has had no apparent recurrence of his novel treatment-related gastrointestinal toxicity.

Disclaimer

The views expressed in this presentation are those of the authors and do not reflect the official policy of the Department of Army/Navy/Air Force, Department of Defense, or U.S. Government.

Acknowledgements

The authors would like to acknowledge the personnel from the William Beaumont Army Medical Center microbiology lab who worked on the diagnostics for this case.

Data Availability Statement

Any data generated or analyzed during this study has been included in the manuscript. No specific datasets were generated or analyzed and as such data sharing beyond the documented clinical summary is not applicable.

References

1. Dromer F, Mathoulin-Pélissier S, Launay O, Lortholary O, Group FCS. Determinants of disease presentation and outcome during cryptococcosis: the CryptoA/D study. PLoS Med. 2007; 4: e21.
2. Chen S, Sorrell T, Nimmo G, Speed B, Currie B, Ellis D, et al. Epidemiology and host- and variety-dependent characteristics of infection due to *Cryptococcus neoformans* in Australia and New Zealand. Australasian Cryptococcal Study Group. Clin Infect Dis. 2000; 31: 499-508.
3. Park BJ, Wannemuehler KA, Marston BJ, Govender N, Pappas PG, Chiller TM. Estimation of the current global burden of cryptococcal meningitis among persons living with HIV/AIDS. AIDS. 2009; 23: 525-530.
4. Centers for Disease C. Revision of the CDC surveillance case definition for acquired immunodeficiency syndrome. Council of State and Territorial Epidemiologists; AIDS Program, Center for Infectious Diseases. MMWR Suppl. 1987; 36: 1S-15S.
5. Kidd SE, Hagen F, Tscharke RL, Huynh M, Bartlett KH, Fyfe M, et al. A rare genotype of Cryptococcus gattii caused the cryptococcosis outbreak on Vancouver Island (British Columbia, Canada). Proc Natl Acad Sci USA. 2004; 101: 17258-17263.
6. Lui G, Lee N, Ip M, Choi KW, Tso YK, Lam E, et al. Cryptococcosis in apparently immunocompetent patients. Qjm. 2006; 99: 143-151.
7. Mitchell DH, Sorrell TC, Allworth AM, Heath CH, McGregor AR, Papanaoum K, et al. Cryptococcal disease of the CNS in immunocompetent hosts: influence of cryptococcal variety on clinical manifestations and outcome. Clin Infect Dis. 1995; 20: 611-616.
8. Mitchell TG, Perfect JR. Cryptococcosis in the era of AIDS--100 years after the discovery of *Cryptococcus neoformans*. Clin Microbiol Rev. 1995; 8: 515-548.
9. Pappas PG, Perfect JR, Cloud GA, Larsen RA, Pankey GA, Lancaster DJ, et al. Cryptococcosis in human immunodeficiency virus-negative patients in the era of effective azole therapy. Clin Infect Dis. 2001; 33: 690-699.
10. Peachey PR, Gubbins PO, Martin RE. The association between cryptococcal variety and immunocompetent and immunocompromised hosts. Pharmacotherapy. 1998; 18: 255-264.
11. Saigal G, Post MJ, Lolayekar S, Murtaza A. Unusual presentation of central nervous system cryptococcal infection in an immunocompetent patient. AJNR Am J Neuroradiol. 2005; 26: 2522-2526.
12. Goldman JD, Vollmer ME, Luks AM. Cryptococcosis in the immunocompetent patient. Respir Care. 2010; 55: 1499-1503.

13. Awasthi M, Patankar T, Shah P, Castillo M. Cerebral cryptococcosis: atypical appearances on CT. Br J Radiol. 2001; 74: 83-85.

14. Perfect JR, Dismukes WE, Dromer F, Goldman DL, Graybill JR, Hamill RJ, et al. Clinical practice guidelines for the management of cryptococcal disease: 2010 update by the infectious diseases society of america. Clin Infect Dis. 2010; 50: 291-322.

15. Stamm AM, Diasio RB, Dismukes WE, Shadomy S, Cloud GA, Bowles CA, et al. Toxicity of amphotericin B plus flucytosine in 194 patients with cryptococcal meningitis. Am J Med. 1987; 83: 236-242.

16. Utz JP, Bennett JE, Brandriss MW, Butler WT, Hill GJ, Ii. Amphotericin B Toxicity: Combined Clinical Staff Conference at the National Institutes of Health. Ann Intern Med. 1964; 61: 334.

17. Sohail MA, Adnan Sohail M, Ikram U. Flucytosine-induced colitis. BMJ Case Rep. 2014; 2014.

18. Fond B, Bentata-Pessayre M, Krivitzky A, Callard P, Dupont B, Delzant G. [Iatrogenic colitis during flucytosine treatment for neuromeningeal cryptococcosis]. Sem Hop. 1983; 59: 1187.

19. Georgescu S, Dubei L, Zaharia M, Cirdei C, Crumpei F, Cijevschi-Prelipcean C, et al. Ogilvie's Syndrome–acute colonic pseudo-obstruction. Case report and review of the literature. Rom J Gastroenterol. 2003; 12: 51-55.