SCIENCEFORECAST
Connecting Research to Drive Scientific Innovation

Case Report
Published: 10 Sep, 2018

SF Journal of Clinical Case Reports

Symptomatic and Functional Improvements Following Chiropractic Care in a Patient with Adult Scoliosis Related to a Congenital Malformation of the Upper Cervical Spinal Anatomy: A Case Report

Oppelt M[1]* and Boots M[2]

[1]Academic Health Center Faculty Clinician – Palmer College of Chiropractic, Davenport IA, USA

[2]Private Practice of Chiropractic – Boots Chiropractic & Wellness Center, Kimberly WI, USA

Abstract

Objectives: To describe the chiropractic care that has delivered beneficial results in a patient with adult scoliosis with probable relation to a congenital malformation of the upper cervical spinal anatomy.

Clinical Features: This case reviews the positive results of advanced Activator Method care – a chiropractic technique–for a 22-year-old female with a rotatory levo-scoliosis of 38 degrees from T9-L2 related to an upper cervical malformation–extensive paracondylar process extending from occiput, measuring 12mm beyond the inferior tip of mastoid, articulating with the left transverse process of atlas (C1 vertebra). This axillary articulation results in a 10.5 degree left lateral tilt of C1 and displays a complete lateral bridge and retrotransverse foramen on the ipsilateral side. Atlas presents with limited motion noted on flexion-extension x-rays and motion palpation. It is proposed the scoliosis is a compensation of the atlas lateral tilt through the righting reflex.

Intervention and Outcomes: The goal of care is to limit scoliotic progression while understanding the upper cervical anomaly and skeletal maturity restrict the ability for structural correction. Since curvature changes will not be noticed nor desired, pain management is the main goal. Maintaining functional motion will decrease myogenous pain generators and increasing patient comfort. The objective through care is to maintain spinal kinetics, muscular and fascial plane mobility, and functional muscular respiration, as well as preserve other possible co-morbid conditions common in scoliotic patients.

The patient reports "much less" pain during her workouts and activities of daily living. This improvement level had been noticed and maintained since week three of treatment. SF-36 questionnaire reflects 20% improvement in seven weeks and 30% improvement over twelve weeks.

Conclusions: This case report reviews the benefits of Activator Method specific chiropractic care for an adult scoliotic patient with relation to an upper cervical spine malformation. Symptomatic and functional improvements are noted. Few studies are published with scoliotic patients past skeletal maturity and even fewer published with relation to a spinal congenital malformation, specifically the upper cervical anatomy. A treatment protocol for pediatric scoliosis seems to be well represented in the literature, but for skeletally mature patients with a moderate to severe scoliosis, bracing is no longer beneficial. Surgery remains recommended for adult patients with a curvature greater than 45 degrees. This case study provides some evidence of positive results with palliative care in adult scoliosis.

Keywords: Scoliosis; Upper Cervical Malformation; Paracondylar Process; Vertebral Subluxation; Chiropractic; Adjustment; Activator Technique

Introduction

Scoliosis is defined as a lateral curvature of the spinal column noted on coronal radiological examination, typically P-A (posterior to anterior), with a Cobb angle greater than 10 degrees: measured from the superior endplate of superior most vertebra involved in the lateral curve to the inferior endplate of the inferior most vertebra [1,2,6]. Nash-Moe Method of body rotation grades

OPEN ACCESS

Correspondence:
Michael Oppelt, Academic Health Center Faculty Clinician – Palmer College of Chiropractic, Davenport IA, USA.
E-mail: *oppelt_m@palmer.edu*

Received Date: *19 Jul 2018*
Accepted Date: *04 Sep 2018*
Published Date: *10 Sep 2018*

Citation: *Oppelt M, Boots M. Symptomatic and Functional Improvements Following Chiropractic Care in a Patient with Adult Scoliosis Related to a Congenital Malformation of the Upper Cervical Spinal Anatomy: A Case Report. SF J Clin Case Rep. 2018; 1(2): 1012.*

ISSN 2643-8194

Copyright *© 2018 Oppelt M. This is an open access article distributed under the Creative Commons Attribution License, which permits unrestricted use, distribution, and reproduction in any medium, provided the original work is properly cited.*

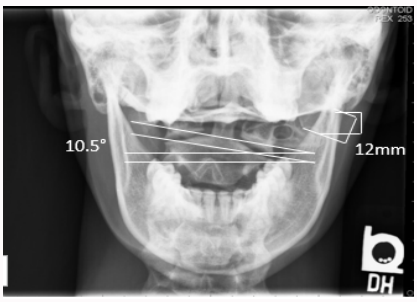

Figure 1: A-P Open Mouth x-ray including line analysis showing a paracondylar process off the left occipital bone measuring 12mm (+/- 2.5mm) caudal from the mastoid process. This additional articulation with the left atlas (C1) transverse process is resulting in a left lateral tilt of atlas measured at 10.5 degrees (+/- 1 degree). Base of skull, measured from mastoid to mastoid, demonstrates a neutral orientation.

Figure 2: A-P Open Mouth x-ray without line analysis.

the amount of rotation in the apical vertebral body involved in the scoliosis, determined from pedicle rotation, which is graded from 0 (normal) to +4 or maximal rotation. Body rotation is important in determining progression and treatment [1,3,4].

Traditionally, scoliotic progression is more common in females specifically during years of puberty, until spinal maturation is typically reached [1,5,6]. Radiological imaging – along with the use of Cobb Angle and Nash-Moe measurements–is an effective tool for monitoring curve progression in which follow-up studies can be performed in as little as four months apart. Scoliosis treatment is highly dependent on the degree and severity of the curvature: curves over 30 degrees have a greater incidence of progressively worsening, especially prior to skeletal maturity [6].

General guidelines state that mild curvatures (<20 degrees) result in monitoring and observation in 4 to 12-month intervals; moderate curvatures (20-45 degrees), or a change in curvature by 5 degrees between consecutive visits, typically result in spinal bracing; and severe curvatures (>45 degrees), or curves that continue to progress despite being braced, are often sent for surgical stabilization through Herrington rods or bony fusion [1].

Risser sign is a classic tool for determining skeletal maturity based on the ossification of the iliac crest and is observed on the A-P (anterior to posterior) lumbo-pelvic x-ray. Risser sign is graded from 0 (least ossification) to 5 (complete ossification), with a Risser sign of 5 indicated a minimal risk of scoliotic progression due to skeletal maturity [1,6]. Only patients with a scoliosis of more than 30 degrees need to be monitored for curvature progression past skeletal maturity. The goal of bracing is to slow curve changes in hopes of avoiding surgery, but for the skeletally mature patients, bracing is no longer viewed as beneficial. Surgery is still recommended for adult patients with a curve beyond 45 degrees. There is some evidence of positive results with palliative care in adult scoliosis [7-12].

Chiropractic care has been shown effective in management of scoliotic care and particularly presents a distinct advantage in early stage scoliosis with curves less than 20 degrees. One study explains, over a one-year treatment plan, 40 children ages 9-15 years of age averaged a 1.4-degree reduction in spinal curvature; children 10 and under averaged 2.6-degree improvements, whereas children over the age of 10 showed an average change of 0.9 degrees [8].

The purpose of the paper is to highlight the benefits this patient experienced with chiropractic care for a scoliotic condition. Also demonstrated is how scoliosis can be secondary to spinal abnormalities, such as an upper cervical congenital malformation. Specifically, with relation to a large paracondylar process altering the position of atlas (C1 vertebra). Maintaining functional motion and movement within the fascial plane spiral line will help manage the musculoskeletal pain generators [23].

Case Presentation

A 22-year-old Caucasian female presents with subjective complaints of neck and upper thoracic pain/tightness. Other complaints include: occasional low back and sacral pain, knee pain, muscle driven tension headaches, and sporadic debilitating migraines.

Patient reports she was diagnosed with a scoliosis since birth and has had pain due to the scoliotic curvatures since puberty, dated 2006. Patient received surgical consultations for scoliotic stabilization. Both her parents and doctors decided to monitor for further progression. No Surgery or bracing were ever performed.

Postural analysis reveals a visual global list to the left with a right high shoulder, left head translation and right fascial rotation. Curvature to the left in the lower thoracic and lumbar spine regions. The patient also presents with hypo- kyphotic and lordotic curvatures.

Exam findings reveal general decreased spinal ranges of motion, a structural scoliosis remaining during orthopedic testing and consistent pain findings in left upper lumbar region. No abnormalities noted in the cardiovascular or respiratory systems.

Radiological examination reveals a loss of anterior-posterior spinal curvatures system-wide. The C-curved scoliosis presents with a 38-degree (+/- 2 degrees) curvature to the left from T9-L2. "Upper cervical malformation noted including a prominent bony process originating from the left para-condylar region of the occiput, articulating with the atlas in the region of the transverse process. Deformity of the left transverse process of C1 is evident. The atlantodental interval is normal" [20]. The para-condylar process extends12mm (+/- 2.5mm) caudally from the occiput acting as a wedge on C1 resulting in a 10.5 degree (+/- 1 degree) left lateral tilt. Mastoid to mastoid measurement reveals no lateral tilt of the cranium (Figure 1). Atlas presents with limited motion noted on flexion-extension x-rays at the occipital-atlantal joint.

The A-P Open Mouth x-ray also displays a retro-transverse foramen formed by a complete lateral bridge off the superior aspect of the proximal portion of the left atlas transverse process to the superior aspect of the left lateral mass [6].

Discussion

Through the righting reflex, otherwise known as the natural

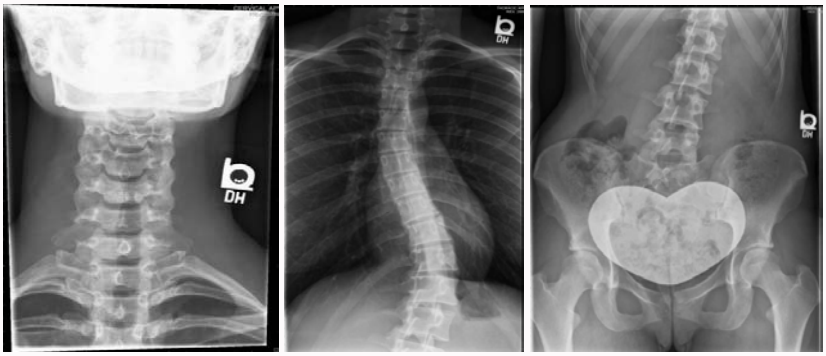

Figure 3: Full spine sectionals stitched together. Scoliosis of 38 degrees (+/- 2 degrees) from T9-L2 is noted Thoracic.

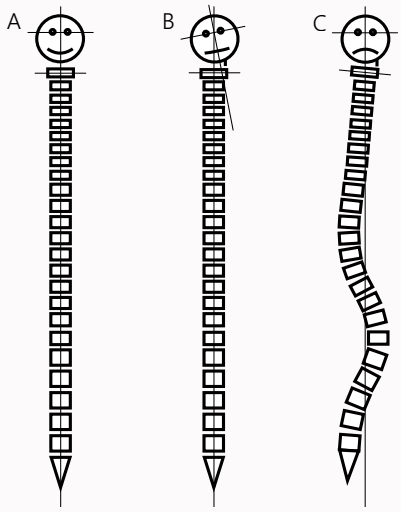

Figure 4: Diagrams are not drawn to scale.
Diagram A: Normal spine with neutral head placement.
Diagram B: Normal spine with para-condylar process resulting in a lateral head tilt, no righting reflex.
Diagram C: Scoliotic spine secondary to the para-condylar process, because of the neutral head placement attributable to the righting reflex.

tendency to level the eyes to the horizon, osseous changes resulting in a lateral tilt of atlas can cause compensatory curves in the lower spinal column. Since the eyes will limit head tilt, the permanent tilt of atlas due to the extensive paracondylar process will result in a neuromuscular reflex creating a lateral list of the cervical spine, transferred to a compensatory scoliotic curvature in the thoraco-lumbar spine. The pain and dysfunction from subluxation, facet syndrome, and myalgia can be directly associated to the scoliosis; whereas, the scoliosis can be linked to the lateral tilt of atlas resulting from its ancillary articulation with the paracondylar process (Figure 4).

The goal of care is to limit scoliotic progression while understanding the upper cervical anomaly and skeletal maturity confine the ability for structural correction. Since curvature changes will not be noticed nor desired, pain management is the main goal.

Maintaining functional motion will decrease myogenous pain generators–increasing patient comfort. The objective through care is to maintain spinal kinetics, muscular and fascial plane mobility, and functional muscular respiration, as well as preserve other possible co-morbid conditions common in scoliotic patients.

The patient had a goal of having better and pain free workouts. After three weeks of treatment the patient reports "much less" pain during and after her workouts and while performing her activities of daily living. This improvement level has been maintained throughout treatment. After eight weeks of treatment the patient no longer noticed the nagging knee pain she had when walking up stairs. At twelve week, the patient continues to respond favorably and states that frequency and severity of neck pain has decreased. SF-36 questionnaire, a valid and reliable measure of the patient's general health (from physical to emotional wellbeing) reflects 20% improvement in seven weeks and 30% improvement over twelve weeks.

Limitations

A major limitation to this study includes absolute certainty in the patient's upper cervical anatomical interaction. It is noted that projectional distortion may be possible in the limited x-ray analysis. A computed tomography (CT) 3D reconstruction of the congenital defect would allow for visualization of the surrounding anatomy and true determination to the extent of the upper cervical malformation influence on the patient's scoliosis.

Conclusion

This study provides information on an adult scoliosis patient with a probable relation to an upper cervical malformation who responded favorably to instrument assisted chiropractic care. A primary pain drive with scoliosis patients is sclerotome pain. There is understanding that fascia is a dominate tissue consideration with muscle therapy. Fascia forms a continuous tensional network throughout the human body, covering and connecting every single organ, every muscle, and even every nerve or tiny muscle fiber. Treatment of the myofascial plane lines, the myofascial asymmetries, and accompanying joint dysfunction markedly reduced the pain. Asymmetrical forces that exert greater force to distort the spine are more likely to be derive from asymmetries of muscles that are at an angle to the spine rather than those muscles that are parallel to it [23]. Movement above the gravitational line generates more spine related stress margins and torsion then do the perpendicular forces needed to stand and resist gravity. The Chiropractic instrument Activator V allows precision thrust angle and vector to deliver a concentrated impulse delivery to influence both the myofascial plane restrictions and muscle fibers, as well as the associated articulation.

The results in this paper apply to our patient as described and is not intended as a global care strategy. All principles can be applicable to scoliosis patients as part of an individualized patient care plan.

References

1. Kim Hana, Hak Sun Kim, Eun Su Moon, Choon-Sik Yoon, Tae-Sub Chung, Ho-Taek Song, et al. "Scoliosis Imaging: What Radiologists Should Know-Erratum". Radio Graphics. 2015; 30: 1823-1843.
2. "Cobb Angle. Radiology Reference Article. Radiopaedia.org". Radiopaedia Blog RSS. N.p., n.d. Web. 2016.
3. Nash CL and John H. Moe. "A study of vertebral rotation." The Journal of Bone & Joint Surgery. 1969; 51: 223-229.
4. Lam Gabrielle C, et al. "Vertebral rotation measurement: a summary and comparison of common radiographic and CT methods." Scoliosis. 2008; 3: 16.
5. D Carter, Olivia and Suzanne G. Haynes. "Prevalence rates for scoliosis in US adults: results from the first National Health and Nutrition Examination Survey". International journal of epidemiology. 1987; 16: 537-544.
6. Morter Harvey B Jr. Anatomy of the Head, Neck, and Back. Davenport, IA: Palmer College of Chiropractic. 2010.
7. Tarola GA. Manipulation for the control of back pain and curve progression in patients with skeletally mature idiopathic scoliosis: two cases. Journal of Manipulative Physiological Therapeutics. 1994; 17: 253-257.
8. "Study on Chiropractic Care for Adolescent Scoliosis Is Encouraging". Study on Chiropractic Care for Adolescent Scoliosis Is Encouraging. N.p., n.d. Web. 2016.
9. Morningstar Mark W. "Outcomes for Adult Scoliosis Patients Receiving Chiropractic Rehabilitation: A 24-month Retrospective Analysis". Journal of Chiropractic Medicine. Elsevier, n.d. Web. 2016.
10. Brooks WJ, Krupinski EA, Hawes MC. Reversal of childhood idiopathic scoliosis in an adult, without surgery: a case report and literature review. Scoliosis. 2009; 4: 27-7161-4-27.
11. Brox JI, Lange JE, Steen H. Comorbidity influenced health-related quality of life of 390 patients with idiopathic scoliosis at long-term follow-up. European Journal of Physical and Rehabilitation Medicine. 2014; 50: 73-81.
12. Woggon Dennis DC. "Can Chiropractic Care Help Scoliosis"? Springer Reference. 2015.
13. "Righting reflex". The American Heritage Science Dictionary. Houghton Mifflin Company. 2016.
14. Fuhr Arlan, ed. Activator methods chiropractic technique. Mosby Incorporated. 1997.
15. Newton Isaac and Florian Cajori. Sir Isaac Newton's mathematical principles of natural philosophy and his system of the world. Univ of California Press. 1946.
16. Blikstad Anja and Hugh Gemmell. "Immediate effect of activator trigger point therapy and myofascial band therapy on non-specific neck pain in patients with upper trapezius trigger points compared to sham ultrasound: a randomised controlled trial". Clinical Chiropractic. 2008; 11: 23-29.
17. Liebschner, Michael AK, et al. "*In Vitro* Biomechanical Evaluation of Single Impulse and Repetitive Mechanical Shockwave Devices Utilized for Spinal Manipulative Therapy". Annals of biomedical engineering. 2014; 42: 2524-2536.
18. Stratemeier PH and SR Jensen. "Partial regressive occipital vertebra". Neuroradiology. 1980; 19: 47-49.
19. Keller Tony S, Colloca Christopher J and Gunzburg Robert. "Neuromechanical characterization of *in vivo* lumbar spinal manipulation. Part I. Vertebral motion". Journal of manipulative and physiological therapeutics. 2003; 26: 567-578.
20. McLean I DC. DACBR, Palmer College of Chiropractic. Radiology Report. 2015.
21. Nolet Paul S, Lawrence Friedman and Deloss Brubaker. "Paracondylar process: a rare cause of craniovertebral fusion-a case report". The Journal of the Canadian Chiropractic Association. 1999; 43: 229-235.
22. Anderson T. Paracondylar process-manifestation of an occipital vertebra. International Journal of Osteoarchaeology. 1996; 6: 195-201.
23. Whyte Ferguson Lucy. Adolescent idiopathic scoliosis: The Tethered Spine III: Is Fascial Spiral the key? Journal of Bodywork & Movement Therapies. 2017; 21: 948-971.