SCIENCEFORECAST
Connecting Research to Drive Scientific Innovation

Case Report
Published: 15 Sep, 2020

SF Journal of Clinical Case Reports

Glass Foreign Body in the Jugular Foramen: Surgery *versus* Conservative Management

Agilinko J[1], Gomati A[1], Keh SM[2], Brewis C[1] and Shakeel M[1]*

[1]*Department of Otolaryngology-Head and Neck Surgery, Aberdeen Royal Infirmary, Aberdeen, United Kingdom*

[2]*Department of Otolaryngology-Head and Neck Surgery, Queen Elizabeth University Hospital, Glasgow, United Kingdom*

Abstract

Introduction: Head and neck foreign bodies are common secondary to penetrating trauma. However, there is not much published literature on foreign body lodged in the jugular foramen. There does not appear to be any agreement on treatment of such a foreign body.

Aims: To share our experience of successful management of a patient with glass foreign body lodged in his jugular foramen.

Methods: Case report and literature review.

Results: A 50-year-old Caucasian male became inebriated and fell on a glass coffee table sustaining a penetrating glass injury to his neck which required surgical exploration. A large piece of glass was removed from the neck uneventfully. Intraoperatively, there was no injury noticed to major neurovascular structures in the neck. Our patient made an uneventful recovery. A post-op CT scan however revealed two small glass foreign bodies impacted in the left jugular foramen. As patient was in a poor general health and also relatively asymptomatic, therefore surgical removal was not instituted. The patient seems not to have had any symptoms related to presence of foreign body in the jugular foramen during the 11 years follow-up period.

Conclusions: Foreign bodies lodged in the jugular foramen are extremely rare. Surgical access to the jugular foramen is complex and is fraught with complications. Therefore, surgical intervention should be avoided unless there are cranial neuropathies due to the presence of foreign body which may worsen over time.

OPEN ACCESS

Correspondence:
Muhammad Shakeel, Department of Otolaryngology-Head and Neck Surgery, Aberdeen Royal Infirmary, Aberdeen, AB25 2ZN, United Kingdom.
E-mail: *drshakeel@doctors.org.uk*

Received Date: *31 Jul 2020*
Accepted Date: *11 Sep 2020*
Published Date: *15 Sep 2020*

Citation: *Agilinko J, Gomati A, Keh SM, Brewis C, Shakeel M. Glass Foreign Body in the Jugular Foramen: Surgery versus Conservative Management. SF J Clin Case Rep. 2020; 3(1): 1027.*

ISSN 2643-8194

Copyright *© 2020 Shakeel M. This is an open access article distributed under the Creative Commons Attribution License, which permits unrestricted use, distribution, and reproduction in any medium, provided the original work is properly cited.*

Introduction

Penetrating neck injury, particularly involving the skull base, can result in significant morbidity and is potentially life-threatening. There is limited literature published on penetrating injuries involving the skull base and less is known about foreign bodies lodged in the jugular foramen. Management of such injury remains controversial despite available algorithms for diagnosis and treatment. Glass can fragment and embed in deeper tissues of the neck in penetrating neck injuries. Therefore, in symptomatic patients it is vital to check for residual fragments even after neck exploration.

This article highlights the principles, challenges and dilemmas faced in managing foreign bodies in the skull base. We share our experience of the diagnostic work-up and management of a patient who sustained a penetrating glass injury to his left neck requiring surgical exploration.

Case Presentation

A 50-year-old Caucasian male presented to the accident and emergency (A&E) department following a fall on a glass coffee table. He sustained a penetrating glass injury to his left neck associated with some bleeding. He was under the influence of alcohol at the time of injury but did not lose his consciousness. His past medical history included personality disorder, self-harm, ischaemic heart disease, cerebral atrophy secondary to chronic alcohol overuse, acute pancreatitis, fibromyalgia and floor of mouth dysplasia (Figure 1). He continued to smoke and drink heavily.

At the time of examination in A&E department he was awake, alert and comfortable. He was haemodynamically stable. There was an obvious glass piece stuck in his left neck but no active bleeding was visible. There was no surgical emphysema on palpation of his neck and upper chest.

Figure 1: Floor of mouth leukoplakia and dysplasia.

Figure 2: Left lower lip weakness secondary to left facial nerve's marginal mandibular branch neuropraxia.

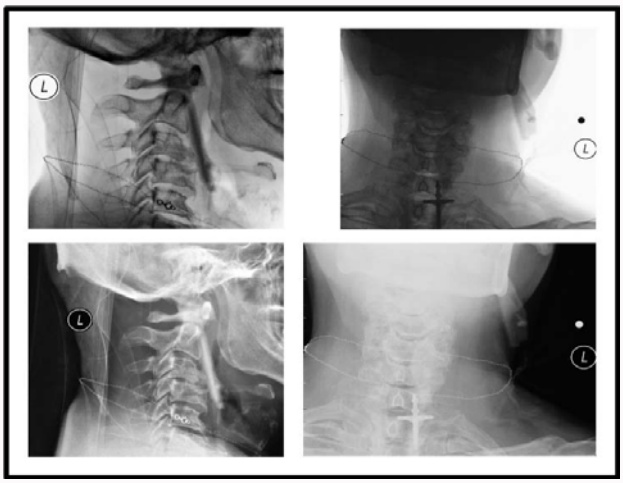

Figure 3: Neck x-ray showing a glass foreign body in the left neck.

He had weakness of the left marginal mandibular nerve (Figure 2). The 9th, 10th, 11th and 12 cranial nerves were all intact. The flexible pharyngolaryngoscopy showed healthy upper aerodigestive tract with no evidence of bleeding or mucosal breach. Both vocal cords were fully mobile.

Anteroposterior and lateral neck x-ray revealed a large 6.5 cm radiopaque fragment projected over the left lateral neck, 4 cm of the length of the fragment was within the subcutaneous tissues (Figure 3). The appearances were in keeping with a shard of glass which was consistent with the history from the patient and clinical findings on examination.

Our patient was taken to theatre where the left neck wound was explored under general anaesthetic. The glass piece had entered the neck at midpoint of the left Sternocleidomastoid (SCM) muscle in zone 2. There was a 2 cm laceration overlying the midpoint of the left SCM (Figure 4). The direction of glass penetration was upward running along the anterior border of the SCM muscle towards the left parotid gland tail. The glass tip reached up to the transverse process of left 2nd cervical vertebra as confirmed with gentle finger palpation (Figure 5). Fortunately, there was no trauma to the major neurovascular structures in the neck. There was some bleeding from the posterior belly of the digastric muscle which was controlled with bipolar diathermy.

Figure 4: Left neck laceration at midpoint of the left sternocleidomastoid muscle (Zone 2)-the patient is lying supine on the operating table and the surgeon is standing on the left side of the patient.

Figure 5: Assessment of left neck wound depth using gentle finger palpation – the patient is lying supine on the operating table and the surgeon is standing on the left side of the patient using his left index finger for palpation.

Figure 6: The left neck wound is closed in layers, a medium suction drain inserted and secured with prolene suture.

One large and one small piece of glass were removed from the left neck uneventfully. No other glass fragment was visible or palpable during his neck exploration. A medium suction drain was inserted and secured with 2/0 prolene suture (Figure 6). Wound closure was obtained with 3/0 vicryl and 4/0 prolene sutures. The patient made an uneventful recovery. Drain was taken out as there was not much drainage overnight.

The patient was discharged home after one-night stay in hospital.

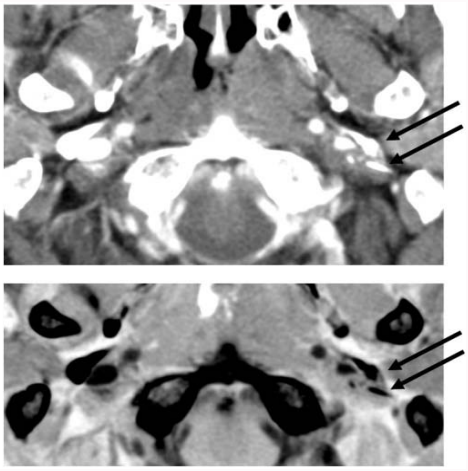

Figure 7: CT scan of the skull base showing two glass foreign bodies in the left jugular foramen (arrows).

A CT scan was carried out after 5 days to rule out any residual glass pieces in the neck. This revealed two radiopaque foreign bodies within the lateral aspect of the left jugular foramen; the superior one measuring 9 mm and the inferior one measuring 4 mm (Figure 7). They were both indenting the Internal Jugular Vein (IJV) which remained patent. There were no focal fluid collections identified.

The patient was reviewed in the skull base clinic where all the cranial nerves were found intact. Radiologically, the left IJV was patent. Because of his significant co-morbidities it was decided not to intervene surgically for his left jugular foramen glass foreign bodies. The patient has not developed any symptoms related to his jugular foramen foreign bodies over the last 11 years.

Discussion

It is rare to encounter a foreign body lodged in the jugular foramen from a penetrating neck injury. The jugular foramen is a large and complex opening in the lateral skull base, located behind the carotid canal. Important structures like cranial nerves IX, X and XI, the inferior petrosal and sigmoid sinuses pass through the jugular foramen.

A plain neck X-ray is often the initial investigation of choice in patients presenting with a neck trauma. This can confirm presence of a foreign body in the neck. Additionally, life-threatening complications of a penetrating neck injury such as surgical emphysema and pneumomediastinum can also be seen, and managed promptly [1]. However, a radiopaque foreign body may be obscured by the cervical vertebrae, resulting in failure to identify this on simple radiograph [2].

Shards of wood and glass are difficult to differentiate on X-rays. This is because shards of wood absorb water molecules and can therefore exhibit a density as low as fat in air [3].

Cross-sectional imaging in the form of CT scan with contrast is the gold standard and this helps in the evaluation of possible injury to neurovascular structures which dictates urgency of subsequent management.

The jugular foramen is bounded by the thick petrous temporal bone anteriorly and occipital bone posteriorly [4]. This makes it difficult for foreign bodies to penetrate and lodge in this area. Therefore, foreign bodies lodged in the jugular foramen present unique challenges to the surgical team because of the complex anatomy of the lateral skull base and the associated surgical morbidity. Complications such as pneumocephalus, intracerebral haemorrhage, contusions, and brain stem injury have been reported in the literature [5].

Our patient underwent an X-ray of his neck in the A&E department. Further imaging in the form of CT scan or angiogram was not considered necessary as there were no worrying signs like active bleeding, expansile haematoma or cranial neuropathies. However, a CT scan was organised 5 days later because of the aggravation of his long standing left neck and shoulder pain. This indeed revealed 2 fragments of the glass deep in the left jugular foramen but these were not considered to be causing any symptoms.

When encountered with potential foreign body lodged in the neck from a penetrating injury, a thorough history-taking, careful physical examination, and appropriate investigations are warranted to help locate the foreign body and other smaller fragments. It is also vital to exclude any potential associated neurovascular and/or aerodigestive tract injuries.

Visible foreign body in the neck should only be removed following a full clinical and radiological evaluation. Cross-sectional imaging in the form of CT scan with contrast helps in the evaluation of possible injury to nerves and vessels which dictates urgency of subsequent management [2]. However, when a patient is haemodynamically unstable, this mandates an urgent surgical exploration and imaging may not be possible before surgery.

Over the last few years, there is growing evidence that surgical neck exploration is not always required, particularly for superficial neck injuries and in patients who are haemodynamically stable with no cranial nerve deficit.

Patients with penetrating neck injuries should be assessed for risk of infection as most foreign bodies are usually contaminated. Antibiotic therapy should be initiated where clinically indicated. Tetanus prophylaxis should be administered to patients whereby their tetanus vaccination is questionable or absent [6]. Infection is the main complication of foreign bodies with a reported overall incidence of 64-70% and mortality rate of 14-57% [7,8]. Broad-spectrum antibiotic, covering both aerobic and anaerobic organism, is generally recommended for a duration of 7-14 days after the injury

Table 1: Literature on penetrating jugular foramen injuries.

Paper	Mechanism of injury	Deep structures injured	Approach	Outcome
Sanders et al. 1988 [10]	K-wire	None	Cervical incision	Successful
Overholt et al. 1992 [11]	Stick (sharp)	CN IX, X and XI	Occipital craniotomy	Successful
Zhao et al. 2004 [12]	Metal nail gun	None	Cervical incision	Successful
Hettige et al. 2010 [13]	Chop stick	Transverse sinus	Occipital craniotomy	Successful
Ito et al. 2012 [4]	Chop stick	Internal jugular vein	Occipital craniotomy	Successful

[9]. Our patient received oral co-amoxiclav for 1 week to prevent any post-operative wound infection.

The decision to proceed with a surgical exploration is based on the haemodynamic status of the patient, depth of tissue penetration, presence of multiple injuries and any associated neurovascular and/or aerodigestive tract injuries. A full informed consent should be sought where possible to outline the benefits and complications of the operation. The aim of surgery should be to explore the wound and to identify any mucosal and neurovascular injuries, especially of cranial nerve IX, X and XI. Early surgical wound debridement with removal of foreign body fragments has been associated with good clinical outcomes [10-14]. Our patient made an excellent recovery following his neck wound exploration and removal of foreign bodies found in the neck.

To date, there is limited published literature on the management of penetrating jugular foramen injury, especially in relation to retained foreign body in this area (Table 1). Our patient sustained a penetrating glass injury to his left jugular foramen. To the best of our knowledge, there is no similar published case in the literature.

In our case, operating in the jugular foramen due to its complex anatomy and associated significant morbidity with patient's poor pre-existing comorbidities had posed a surgical dilemma. There is currently no literature published on comparative outcomes of conservative and surgical management of skull base foreign bodies as these are rarely encountered.

Although all the cases reviewed (Table 1) had surgical extraction of the foreign body, the current literature suggests that foreign bodies without vascular injuries; lying adjacent to important structures and difficult to extract for example in the brain, should be left there as aggressive attempt at extraction of these foreign bodies could lead to poorer outcome and rarely fatality [15]. In our patient, as he remained asymptomatic and had elected not to have further surgery, surgical removal of the residual glass debris from his jugular foramen was not instituted.

Although management algorithm can be a helpful guide, management should be individualised with careful consideration of all options. In patients presenting with a retained foreign body in the jugular foramen, conservative treatment with long-term monitoring should be considered whereby the risk of surgery outweighs the benefits.

Learning Points

Jugular foramen foreign bodies are extremely rare.

Surgical access to the jugular foramen is complex and is fraught with complications.

Surgery should be reserved for patients presenting with cranial neuropathies and/or has vascular compromise.

Neuroradiology is critical in surgical planning.

Such patients should be looked after by a specialist skull base team.

Declaration

The photographs shown in this article are taken from our collection to describe the clinical situation of the patient discussed here.

References

1. Luo Y, Yuan H, Cao ZS. Residual foreign body in the neck after trauma results in the delayed rupture of the common carotid and internal jugular vein: a case report. J Med Case Rep. 2013; 7: 13.
2. Kantarci M, Ogul H, Karasen RM. Detection of a giant wooden foreign body with multidetector computed tomography and multiplanar reconstruction imaging. Am J Emerg Med. 2007; 25: 211-213.
3. Specht CS, Varga JH, Jalali MM, Edelstein JP. Orbitocranial wooden foreign body diagnosed by magnetic resonance imaging. Dry wood can be isodense with air and orbital fat by computed tomography. Surv Ophthalmol. 1992; 36: 341-344.
4. Daniels DL, Williams AL, Haughton VM. Jugular foramen: anatomic and computed tomographic study. AJR Am J Roentgenol. 1984; 142: 153-158.
5. Kim JJ, Gean A. Imaging for the diagnosis and management of traumatic brain injury. Neurotherapeutics. 2011; 8: 39-53.
6. Nishio Y, Hayashi N, Hamada H, Hirashima Y, Endo S. A case of delayed brain abscess due to a retained intracranial wooden foreign body: a case report and review of the last 20 years. Acta Neurochir. 2004; 146: 847-850.
7. Chunhua Q, Qun W. A late-onset seizure due to a retained intracranial foreign body-pencil lead: a case report and review. J Craniofac Surg. 2014; 25: e109-e110.
8. Dunn IF, Kim DH, Rubin PA, Blinder R, Gates J, Golby AJ. Orbitocranial wooden foreign body: a pre-, intra-, and postoperative chronicle: case report. Neurosurgery. 2009; 65: E383-E384.
9. Williams JR, Aghion DM, Doberstein CE, Cosgrove GR, Asaad WF. Penetrating brain injury after suicide attempt with speargun: case study and review of literature. Front Neurol. 2014; 5: 113.
10. Sanders AD, Wolff AP, Ciric I, Mikhael M. Kirschner wire migration through the jugular foramen. Ann Otol Rhinol Laryngol. 1988; 97: 559-560.
11. Overholt EM, Dalley RW, Winn HR, Weymuller EA. Penetrating trauma of the jugular foramen. Ann Otol Rhinol Laryngol. 1992; 101: 452-454.
12. Zhao X, Liu J, Guo Y. Removal of a large metallic foreign body from the base of the left skull. J Otolaryngol. 2004; 33: 120-122.
13. Hettige S, Kok K, Epaliyanage P, Thomas NW. Chopstick injury penetrating the skull base: a case report. Skull Base. 2010; 20: 219-222.
14. Ito M, Kumagai K, Sakay N, Fikushima Y, Hamada Y. Penetrating transoral cranial injury by a chopstick through the jugular foramen: report of a case. Br J Oral Maxillofac Surg. 2012; 24: 101-105.
15. Zhang D, Chen J, Han K, Yu M, Hou L. Management of Penetrating Skull Base Injury: A Single Institutional Experience and Review of the Literature. Biomed Res Int. 2017.