SCIENCEFORECAST
Connecting Research to Drive Scientific Innovation

Research Article
Published: 17 Apr, 2018

SF Journal of Clinical Pathology

Clinicopathological Studies on the Effect of Some Antibacterial Medicinal Plants in Broilers

Omnia E Kilany[1]*, Youssef F[2], Mabrouk M[2] and IM Fares[3]

[1]Suez Canal University, Faculty of Veterinary Medicine, Department of Clinical Pathology, Ismailia, Egypt

[2]Animal Health Research Institute, Department of Clinical Pathology, Ismailia, Egypt

[3]Department of Animal Hygiene, Zoonosis and Behavior, Egypt

Abstract

In trial to investigate the immunostimulant and antioxidant activities of *Moringaoleifera and Sweet basil* as a natural feed additives on chicken. A total of 120 one- day- old, broiler chickens (Cobb) were randomly assigned to 6 groups, each of 20 as follows: G1 (control); G2 (5% *Moringaoleifera*); G3 (0.5% *Sweet basil*); G4 (*E. coli* 2×10^7 cfu); G5 (5% *Moringaoleifera* and *E. coli*) and G6 (0.5% *Sweet basil* and *E. coli*). The total body weight, immune response and antioxidant parameters as well as histopathological investigation were detected. There were significant decreases in live body weight and body weight gain in the infected group. While, infected treated groups resulted in a significant increase in total body weight compared to the infected group. The immunological results, there were a significant increase in the level of interleukin 6, IgG and IgM in the infected group as compared to control. While, infected treated groups showed a significant decrease as compared to the infected group. The antioxidant parameters results, there were a significant increase in MDA level with a significant decrease in SOD and GSH levels in the infected group as compared to control. While, infected treated groups showed a significant decrease in MDA level and a significant increase in SOD and GSH levels as compared to the infected group. The histopathological examination, there were vacuolar degeneration of hepatocytes and lymphocyte infiltration, destruction and shortening of intestinal villi, focal necrosis of renal tubules with massive aggregation of lymphocytes and there was lymphoid depletion in bursa, thymus and spleen in the infected non treated group. While, the treated groups observed improvement in lesions as compared to infected group. It could be concluded that *Moringaoleifera* and *Sweet basil* has a role as immune response and antioxidant as well as controlling and prevention of *E. coli* infection.

Keywords: *E. coli; Moringaoleifera; Sweet basil;* MDA; SOD; GSH; IgM and IgG

Introduction

Moringaoleifera is a potential plant that could be used to enhance immune responses and to improve intestinal health of broiler chicken. Hence, *Moringa* has a great potential in improving nutrition and strengthening immune functions of boiler chicken and it's also contains very high antioxidants compounds [1].

Sweet Basil contains phytochemicals (glycoside, gums, mucilage, proteins, amino acids, tannins, phenolic compound, triterpenoids steroids, sterols, saponins, flavones and flavonoids) with significant nutritional, antioxidant capabilities and health benefits [2]. *Sweet basil* showed inhibitory effect on *Escherichia coli, Klebsiella pneumonia, Staphylococcusaureus, Pseudomonas aeruginosa* and *Proteus spp.* [3]. The addition of *Sweet basil* to broilers diet improved the immune status [4].

Avian colibacillosis is an infectious disease of birds caused by *Escherichia coli*, which is considered as one of the principal causes of morbidity and mortality, associated with heavy economic losses to the poultry industry by its association with various disease conditions, either as primary pathogen or as a secondary pathogen [5]. This disease has an important economic impact on poultry production worldwide. The majority of economic losses results from mortality and decrease in productivity of the affected birds [6]. The aim of these work to investigate the effect of adding *Moringaoleifera* 5% and *ocimumbasilicum* 0.5% as feed additives on body weight, immune response, antioxidant and histopathological examination on experimental broiler chicken which infected by *E. coli.*

OPEN ACCESS

Correspondence:
Omnia E Kilany, Suez Canal University, Faculty of Veterinary Medicine, Department of Clinical Pathology, Ismailia, Egypt.
E-mail: *omniakilany@vet.suez.edu.eg*

Received Date: *12 Mar 2018*
Accepted Date: *12 Apr 2018*
Published Date: *17 Apr 2018*

Citation: *Kilany OE, Youssef F, Mabrouk M, Fares IM. Clinicopathological Studies on the Effect of Some Antibacterial Medicinal Plants in Broilers. SF J Clin Pathol. 2018; 1(1): 1003.*

ISSN 2690-4187

Copyright *© 2018 Omnia E Kilany. This is an open access article distributed under the Creative Commons Attribution License, which permits unrestricted use, distribution, and reproduction in any medium, provided the original work is properly cited.*

Materials and Methods

One hundred and twenty, one day old, Cobb broiler chicks with an average body weight 45-50 gm were obtained from Ismailia/ Misr Poultry Company. The chicks were housed in floor pens and randomly classified into 6 groups of 20 birds each and reared for 42 days (6 Wks.). Feed and water were provided *ad libitum*. All chicks were fed on commercial broiler starter basal ration from 1st day of old until reached 3 weeks of age then grower finisher ration were used until end of experiment at 6 weeks of age. The diet was formulated to meet the nutritional requirements as suggested by the NRC [7]. The birds were vaccinated [Newcastle disease (ND), Gumboro infectious bursal disease (IBD)]. Vaccine was used at 14th and 25th day of age as eye drop [8].

Moringaoleifera and *sweet basil* leaves brought from field in Ismailia, cleaned and powdered for use.

Experimental design

One hundred and twenty apparent healthy chicks were divided randomly into six equal groups, each group contain 20 chicks reared for 6 weeks as in the following: G1 as the control; G2 received 5% *Moringaoleifera* supplement; G3 received 0.5% *Sweet basil*; G4 infected by *E. coli* only; G5 infected and treated by 5% *Moringaoleifera* and G6 infected and treated by 0.5% *Sweet basil*.Chicks in groups 4, 5 and 6 were inoculated with 0.5 ml saline suspension containing 2×10^7 C.F.U. of *E. coli* by intranasal route at 21 days of age according to method described by Peighambari et al. [9]. The total body weight and weight gain were determined according to Brady [10].

Blood samples: they were collected from wing vein and serum was separated preserved in -20° C until to determine the immunological and antioxidant parameters.

Determination of immunological parameters: IgG and IgM was performed by Enzyme linked immunosorbent assay (ELISA) using ELISA Kit according to Larson [11]. Chicken Interleukin 6 (IL6) was determined according to Wajent [12].

Determination of antioxidant parameters: MDA was determined by using Bio diagnostic kit. No. MD 25 29 which is based on the spectrophotometric method of Ohkawa [13]. Superoxide dismutase (SOD) activity was assayed by using Bio diagnostic kit No. SD 25 21 according to Nishikimi et al. [14]. The assay of glutathione reduced level (GSH) was performed using Bio- diagnostic kit No. GR 25 11 which is based on the spectrophotometric method of Beutler [15].

Histopathological examination: Specimens from liver, kidney, spleen, bursa, thymus and intestine were obtained from all sacrificed chicken. Samples were preserved in 10 % formalin and embedded in paraffin wax. Sectioned at 5-micron thickness and stained with haematoxylin and eosin (H and E) for histopathological examination [16].

Statistical analysis

The obtained data from treated groups were statistically analyzed in compare to control group for the mean and standard error using SPSS 10 [17]. Differences between means of different groups was carried out using one way ANOVA with Duncan multiple comparison tests according to Snedecor and Cochran [18].

Results and Discussion

In the present study, *E. coli* infected group showed a significant decrease (P<0.05) in the body weight and body weight gain. These results agreed with Russel and Ask et al. [19,20] reported that colibacillosis caused growth retardation in chicken.

Table 1: The effect of *Moringaoleifera* and *Sweet basil* on mean live body weight and body weight gain (g) on healthy and *E. coli* experimentally infected groups.

Group	Body weight	Body weight gain
G1	2164.1±18.50^{bc}	445.52±2.89^{c}
G2	2261.8±21.10^{ab}	449.65±2.89^{bc}
G3	2323.1±23.80^{a}	488.2±2.89^{a}
G4	1928.2±17.00^{d}	405.30±2.89^{d}
G5	2171.2±24.60^{bc}	458.2±2.89^{b}
G6	2118.8±18.40^{c}	445.00±2.89^{c}

Table 2: The effect of *Moringaoleifera* and *Sweet basil* on immunoglobulin and interleukin on healthy and *E. coli* experimentally infected groups after 6 weeks.

Group	IgM (mg/ml)	IgG (mg/ml)	IL6 (Pg/ml)
G1	24.90±2.94^{c}	504.0±2.31^{c}	70.09±0.895^{c}
G2	25.0±4.04^{c}	509.0±3.46^{c}	70.28±2.28^{c}
G3	26.15±2.40^{c}	507.50±4.33^{c}	62.68±1.47^{d}
G4	55.50±0.289^{a}	693.50±3.18^{a}	101.42±2.29^{a}
G5	41.50±2.02^{b}	640.0±17.3^{b}	83.06±2.58^{b}
G6	43.50±0.289^{b}	625.50±3.18^{b}	71.67±0.707^{c}

While, infected groups and supplemented with *Moringaoleifera* and *Sweet basil* significantly increased body weight and body weight gainin comparing to the infected group.

On the other hand, *Moringaoleifera* treated group showed non-significant increase (P<0.05) in body weight and body weight gain in comparison with control, these results came in agreement with Onunkwo and George [21] who reported that there was no significant difference in average daily weight gain and body weight in broilers fed on *Moringaoleifera* leaf meal up to 10% compared with control. While, *Sweet basil* treated group significantly increased body weight and body weight gain in comparison with control, these results came in agreement with Thair and Galib [22]. These results may be due to the inhibitory effect of MO and SB in colonization of pathogenic *E. coli* which agreed with Ravid et al., [23] who suggested that linalool is the most active agent in *Sweet basil* responsible for antibacterial activity which caused an increase in broilers body weight gain. Also, Yang et al., [1] reported that feeding MO in the diets of broiler chicken significantly enhanced immune responses and reduced *E. coli* and increased *Lactobacillus* counts in ileum. Hence, the *Moringaoleifera* improved the intestinal health and growth performance of the chicken. These results were proved by the histopathological work, *Moringaoleifera* infected birds demonstrated some degenerative changes of the intestinal architecture, but less than that picture recorded in infected group. *Sweet basil* infected birds showed normal villus architecture with mild cellular infiltration in intestinal mucosa and sub-mucosa.

Immunoglobulins are normally produced by B cell to regulate immune system especially humoral immunity. Their production is in response to environmental substances (molecules or microbes) that gain access into the body [24].

Regarding to immunoglobulin results, there was a significant

Table 3: The effect of moringa*oleifera* and *sweet basil* on antioxidant on healthy and *E. coli* experimentally infected groups after 6 weeks.

Group	MDA (nmol/ml)	SOD (U/ml)	GSH (mmol/L)
G1	50.06±4.28[c]	4.64±0.41[a]	3.85±0.35[a]
G2	55.8±8.36[c]	4.78±1.21[a]	3.82±0.72[a]
G3	56.97±1.58[bc]	4.67±0.15[a]	3.79±1.12[a]
G4	87.56±2.44[a]	2.31±0.55[c]	2.25±0.37[c]
G5	68.94±4.87[b]	3.31±0.18[b]	3.16±0.91[b]
G6	62.21±3.50[bc]	3.47±0.05[b]	3.15±0.38[b]

Values are expressed as means ± standard error (SE); n=6.
Means within the same column with different superscripts are significantly different (P<0.05).

increase (P<0.05) in IgG and IgM levels in *E. coli* infected group (G4) compared with control group. These results agreed with Eleiwa et al. [25], who demonstrated a significant increase in the values of IgM & IgG compared with the control group in *E. coli* infected birds. IgM is predominantly found in blood for neutralization of infectious agent in the early stage of the disease and the peak IgM levels occur at 21 days [26].

Meanwhile, the infected groups and supplemented with *Moringaoleifera* and *Sweet basil* (G5 and G6) showed a significant increase as compared to the control group, but less than the infected group due to their immunostimulatory activity as stated by [27,28]. Immunomodulatory potential of *M. oleifera* leaves could be attributed for the presence of flavonoids, polyphenols and terpenoids [29]. Also Ethanol extract of *O. basilicum* has high amounts of polyphenols and flavonoids [30].

While there were no significant changes (P<0.05) in IgG and IgM levels of *Moringaoleifera* and *Sweet basil* treated groups in compared to control group. These results agreed with Ojeka et al., [31] who observed non-significant changes in IgG and IgM in wister rats administrated aqueous leaf extract of *Moringaoleifera*. In contrast to Kahilo et al. [28] showed that, the level of IgG and IgM significantly increased in broiler treated with basil.

Interleukin 6 is secreted by T cells and macrophage to simulate immune response e.g. during infection and after trauma, especially burns or other tissue damage leading to inflammation. IL6 also plays a role in fighting infection. IL6's role as anti-inflammatory cytokine is mediated through its inhibitory effects on TNF-alpha and activation of IL1 and IL10 [32]. Also IL-6 is a pleiotropic cytokine that has both pro inflammatory and anti-inflammatory functions that affect processes ranging from immunity to tissue repair and metabolism. It promotes differentiation of B cells into plasma cells, activates cytotoxic T cells, and regulates bone homeostasis [33].

The present results showed that, there were a significant increase (P<0.05) in IL6 levels in *E-coli* infected groups compared with control group, this result agreed with that of Weinstein et al., [34] who found that, invasion of bacterial organism into human or murine epithelial cells resulted in the production of high levels of IL6 and Nakamura et al., [35] who showed that *E. coli* lipopolysaccharide in chicks may elevate IL6.

On the other hand, the infected groups treated with *Moringaoleifera* and *Sweet basil* showed a significant decrease in IL6 as compared to the infected group. This finding may be attributed to the anti-inflammatory effect of MO and SB. The essential oil of OB and its main compound estragole had anti-inflammatory activity [36]. Ethanol extract of *O. basilicum* has anti-inflammatory effects partly due to high amounts of polyphenols and flavonoids [30]. Also the anti-inflammatory effect of the *Moringaoleifera* leaf extract was due to the presence of flavonoids, tannins and saponins [37].

Meanwhile, *Moringaoleifera* treated group showed non-significant change (P<0.05) in IL6 compared with control group in contrast to Oyewo et al., [38] who reported that, the serum IL-6 concentration decreased significantly in rats administered the aqueous leaf extract of *Moringaoleifera*. While *Sweet basil* treated group showed a significant decrease in IL6 in comparison with control group, these result goes parallel with the result obtained by Yadav et al., [39] who found that, the ethanol-water extract of *ocimum basilicum* leaves in rats significantly reduced the level of IL-6 when compared with toxin group.

Antioxidant enzymes and the determination of MDA concentrations are among the most widely used methods for determination of oxidative stress [40].

MDA is the main final product of lipid peroxidation and has been often used for determining oxidative damage which is indicated by increase its level [41].

The serum MDA level was significantly increased (P<0.05) in *E. coli* infected group as compared to control, this result was agreed with Yazar et al., [42] as bacterial LPS (endotoxin) induces extensive damage to a variety of organs, including liver, due to the increased production of reactive oxygen intermediates and a resultant rise in lipid peroxidation [43]. The serum SOD and GSH levels were significantly decreased in *E. coli* infected group as compared to control, this result was agreed with Konukoglu et al., [44] who evaluated that the levels of peritoneal tissue GSH were significantly lower in *E. coli* induced peritonitis in rats than the control group and Eslami et al., [45] who showed that, the level of SOD significantly decreased in serum of rat injected with *E. coli* lipopolysaccharide compared to control. The reactive oxygen species (ROS) massively released from leukocytes during oxidative stress would indirectly be reduced by GSH peroxidase into alcohols, leading to the parallel oxidation of GSH. So decreases of GSH concentrations in tissue would be occur [46]. In contrast to Yazar et al., [42] who reported that, hepatic SOD activity was not affected in mice experimentally infected with *E. coli*.

On the other hand, the infected groups treated with *Moringaoleifera* and *Sweet basil* showed a significant decrease in MDA with a significant increase in SOD and GSH levels as compared to the infected group. These findings were due to antioxidant activity of MO and SB. *Moringaoleifera* contained large amounts of β-carotene, ascorbic acid (Vit. C), α-tocopherol (Vit. E) [1], these compounds have potent antioxidant activity [47]. Also the antioxidant effect of *Moringaoleifera* leaf extract was due to the presence of polyphenols, tannins, anthocyanin, glycosides, and thiocarbamates, which remove free radicals, activate antioxidant enzymes, and inhibit oxidases [48]. Two phenolic compounds, rosmarinic acid and caffeic acid were identified as strong antioxidant constituents of the *sweet basil* [49]. The essential oils found in OB have major components as linalool, isoanethole and eugenol which have potent antioxidant activities [50].

While, the *Moringaoleifera* and *Sweet basil* treated groups showed non-significant difference in MDA, SOD and GSH levels in comparison with control, these results agreed with Mahajan et al.,

[51] who found that, ethanolic extract of *Moringaoleifera* seeds non-significantly change SOD and GSH levels as compared to control rats and Sakr and Al-Amoudi [52] who showed that, there was no significant difference in the renal activities of SOD enzyme among the control group and *O. basilicum* group in rat. In contrast to Kahilo et al., [28] who found that, MDA significantly decreased while GSH and SOD significantly increased in broiler treated with basil and Allam et al., [53] who reported that, SOD significantly increased beside significant decrease in MDA in broiler supplemented with Moringa leaf extract.

The histopathological examination

Liver: *E. coli* infected non treated group revealed marked degenerative changes among hepatocytes, mononuclear leukocytic cells infiltration, congestion and dilatation of the central vein and sinusoids as well as vacuolar degeneration in hepatocytes. On the other hand, *Moringaoleifera* infected bird's demonstrated mild degenerative changes in hepatocytes with mild mononuclear cellular infiltration. While *Sweet basil* infected birds showed diffuse degenerative changes in hepatocytes and mild congestion of the central vein Photo 1 .

Kidney: *E. coli* infected group showed marked degenerative changes of tubular cells and focal lymphocytic infiltration in interstitial tissue. The degenerative changes of tubular cells were indicated by vacuolar degeneration. Meanwhile, *Moringaoleifera* infected birds demonstrated mild congestion of intertubular blood vessels and mild degenerative changes. Also *Sweet basil* infected birds (G6) showed mild congestion of intertubular blood vessels and mild degenerative changes.

Intestine: *E. coli* infected group revealed degeneration, necrosis, sloughing and desquamation of epithelium of intestinal villi along with severe leukocytic infiltration associated with edema and necrosis of muscularis mucosa, shortening and atrophy of villi with degeneration of glands. *Moringaoleifera* infected birds demonstrated some degenerative changes of the intestinal architecture, but less than that picture recorded in infected group alone. Meanwhile, *Sweet basil* infected birds showed normal villus architecture with mild cellular infiltration in intestinal mucosa and sub-mucosa when compared with the control Photo 2.

Spleen: *E. coli* infected group revealed noticeable pathological changes among splenic parenchyma, these changes include lymphocytic depletion and degeneration. As well as congested areas within the splenic red pulp were noted. Marked increasing of the red pulp area on the expense of the white one was also observed. *Moringaoleifera* infected birds demonstrated a significant difference from that of infected birds without any treatment including relative improvement of white pulp containing small sized lymphoid follicles with mild to moderate congestion of splenic blood vessels along red pulp. *Sweet basil* infected birds (G6) splenic parenchyma restored its architecture to almost the normal picture with mild congestion of splenic blood vessels.

Thymus: *E. coli* infected groupshowed marked lymphocytic depletion when compared to the control group along with blood vessels congestion and extravasated haemo-biotic cells. Lymphocytic necrotic areas were also noted near the area of thymic cortex and the boundaries between the cortex and medulla were mingled together (photo 5D). *Moringaoleifera* and *sweet basil* infected birds demonstrated thymic architectural improvements, but the best pictures Photo 3.

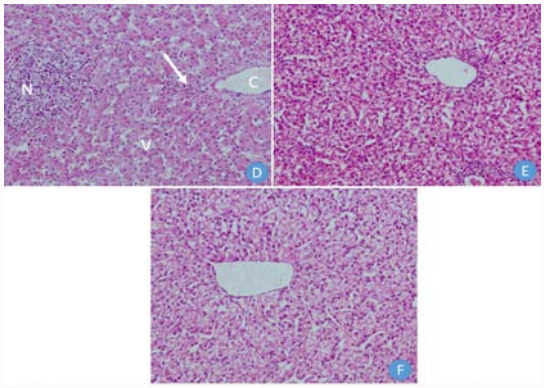

Photo 1: Photomicrographs of broiler liver: D. infected group showing vacuolar degeneration of hepatocytes (V), lymphocytic infiltration around the central vein (arrow), necrotic area (N) and congestion and dilatation of central vein ©. E. MO infected group showing mild vacuolar degeneration and mild small focal lymphatic aggregation. F. SB infected group showing diffuse vacuolar degeneration of hepatocytes. H & E. X200.

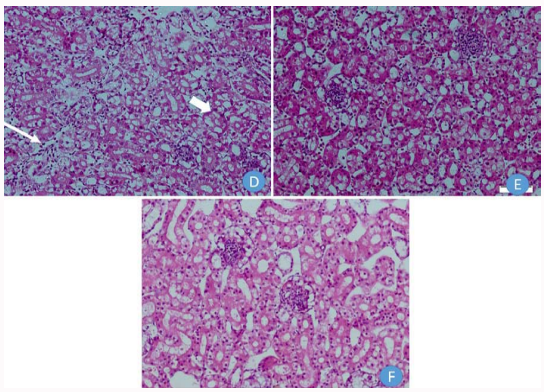

Photo 2: Photomicrographs of broiler kidney: D. Infected group showing marked vacuolar degenerative changes of tubular cells (thick arrow) with areas of interstitial infiltration of mononuclear cells (thin arrow). E. MO infected group and F. SB infected group showing mild vacuolar degeneration of tubular epithelium. H & E. X200.

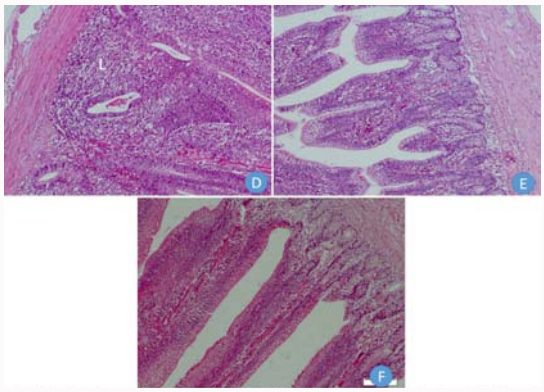

Photo 3: Photomicrographs of broiler intestine: D. Infected group showing destruction of villi, loss and necrosis of intestinal glands along with massive leukocytic infiltration (L). E. MO infected group showing fairly normal villi, glandular and intestinal epithelium along with activation of goblet cells. F. SB infected group showing long healthy villi, normal glandular and intestinal epithelium have numerous goblet cells. H & E.X200.

Bursa of fabricius: *E. coli* infected group showed mild to moderate lymphoid depletion with severe diffuse edema of the interfollicular connective tissue in the lamina propria. Regarding *Moringaoleifera*

infected birds showed mild depletion of lymphocytes in lymphoid follicles. Also *Sweet basil* infected birds showed mild depletion of lymphocytes in lymphoid follicles.

These changes recorded in the liver, kidney and intestine in the present study came in parallel with that recorded by Dho-Moulin and Fairbrother and Manimaran et al., [54,55] **.** There was lymphoid depletion in bursa, thymus and spleen**,** this result agreed with Nakamura et al., [56] who reported that *E.* coli infection induce damage in the immune systems of the chickens including lymphocyte depletion in both bursa and thymus.

Groups that fed *Moringaoleifera* and *Sweet basil* showed normal histological architecture of liver, kidney, intestine, spleen, thymus and bursa. These results came in agreement with Sakr and Al-Amoudi, Owolabi and Ogunnaike, Lu et al. [52,57,58] in laying hens and Kavoi et al., [59] in broiler chicks. Meanwhile, Allam et al., [53] revealed hepatic tissue congestion and hyperplasia in bile duct epithelium, renal tubules undergo interstitial aggregation of lymphocytes and regeneration, intestine showed slight edema, spleen and bursa showed hyperplasia of lymphocyte in broiler chicks supplemented *Moringaoleifera* alcoholic extract.

Conclusion

It could be concluded that the *Moringaoleifera* and *Sweet Basil* were more potent in growth performance, immune response and antioxidant action on broiler chicks. So, advised every farmer to use Moringa and basil as feed additives.

References

1. Yang R-Y, Chang L-C, Hsu J-C, Weng BB, Palada MC, Chadha M, et al. Nutritional and functional properties of Moringa leaves–From germplasm, to plant, to food, to health. In Proceedings of the Moringa and other Highly Nutritious Plant Resources: Strategies, Standards and Markets for a Better Impact on Nutrition in Africa, Accra, Ghana. 2006; pp. 1–9.
2. Jayasinghe C, Gotoh N, Aoki T, Wada S. Phenolics composition and antioxidant activity of *sweet basil* (*Ocimum basilicum L.*). Journal of Agricultural and Food Chemistry. 2003; 51: 4442-4449.
3. Durga KR, Karthikumar S, Jegatheesan K. Isolation of potential antibacterial and antioxidant compounds from *Acalypha indica* and *Ocimum basilicum*. African Journal of Plant Science. 2010; 4: 160-163.
4. Osman M, Yakout H, Motawe H, El-Arab WE. Productive, physiological, immunological and economical effects of supplementing natural feed additives to broiler diets. Poult. Sci. 2010; 30: 25-53.
5. Kabir S. Avian colibacillosis and salmonellosis: a closer look at epidemiology, pathogenesis, diagnosis, control and public health concerns. International journal of environmental research and public health. 2010; 7: 89-114.
6. Otaki Y. Poultry disease control programme in Japan. Asian Livestock (FAO). 1995; 20: 65-67.
7. NRC. Nutrient requirements of poultry. National Academy Press Washington, DC. 1994.
8. Giambrone J, Ronald P. Vaccination of one day-old broiler chicks against Newcastle disease and infectious bursal disease using commercial live and/or inactivated vaccines. Avian diseases. 1986; 30: 557-562.
9. Peighambari S, Julian R, Gyles C. Experimental *Escherichia coli* respiratory infection in broilers. Avian Diseases. 2000; 44: 759-769.
10. Brady W. Measurements of some poultry performance parameters. Veterinary Record. 1968; 88: 245-260.
11. Larsson A, Balow R-M, Lindahl TL, Forsberg P-O. Chicken antibodies: taking advantage of evolution—a review. Poultry science. 1993; 72: 1807-1812.
12. Wajant H, Pfizenmaier K, Scheurich P. Tumor necrosis factor signaling. Cell Death Differentiation. 2003; 10: 45-65.
13. Ohkawa H, Ohishi N, Yagi K. Assay for lipid peroxides in animal tissues by thiobarbituric acidreaction. Analytical biochemistry. 1979; 95: 351-358.
14. Nishikimi M, Rao NA, Yagi K. The occurrence of superoxide anion in the reaction of reduced phenazine methosulfate and molecular oxygen. Biochemical and biophysical research communications. 1972; 46: 849-854.
15. Beutler E, Duron O, Kelly B. Improved method for the determination of blood glutathione. The Journal of laboratory and clinical medicine. 1963; 61: 882-888.
16. Bancroft J, Stevens A, Turner D. Theory and practice of histological technique 3rd ed. Churchill, Livingstone, Edinburgh, London, Melbourne and New York. Melbourne Publishers. 1990.
17. Coakes S, Steed L, Ong C. Analysis without Anguish Using SPSS Version 16 for windows. John Willey & Sons Australia, Milton, Qld. 2009.
18. Snedecor G, Cochran W. Statistical methods 8th Ed Iowa State Univ. Press, Ames, Iowa-50010. 1989.
19. Russell S. The effect of airsacculitis on bird weights, uniformity, fecal contamination, processing errors, and populations of *Campylobacter spp.* and *Escherichia coli*. Poultry Science. 2003; 82: 1326-1331.
20. Ask B, Van der Waaij E, Van Eck J, Van Arendonk J, Stegeman J. Defining susceptibility of broiler chicks to colibacillosis. Avian pathology. 2006; 35: 147-153.
21. Onunkwo DN, George OS. Effects of Moringa Oleifera Leaf Meal on the Growth Performance and Carcass Characteristics of Broiler Birds. IOSR Journal of Agriculture and Veterinary Science. 2015; 8: 63-66.
22. Thair JKA-K, Galib MA-K. Evaluation of *Sweet Basil* Powder Plant (*Ocimum basilicum L.*) as a Feed Additives, on the Performance of broiler Chicks. The Iraqi Journal of Veterinary Medicine. 2013; 37: 52-58.
23. Ravid U, Putievsky E, Katzir I, Lewinsohn E. Enantiomeric composition of linalol in the essential oils of *Ocimum* species and in commercial basil oils. Flavour and fragrance journal. 1997; 12: 293-296.
24. Smith KA. Interleukin-2: inception, impact, and implications. Science. 1988; 240: 1169-1176.
25. Eleiwa NZ, El Sayed E, Nazim A. Prophylactic and therapeutic evaluation of the phytobiotic (Orego-stim)® in chicken experimentally infected with *E. coli*. J. Am. Sci. 2011; 7: 91-102.
26. Flaherty DK. Chapter 9 - Antibodies A2 In: Immunology for Pharmacy. Mosby, Saint Louis. 2012; 70-78.
27. Sudha P, Asdaq SMB, Dhamingi SS, Chandrakala GK. Immunomodulatory activity of methanolic leaf extract of moringa oleifera in animals. Indian J Physiol Pharmacol. 2010; 54: 133–140.
28. Kahilo K, El kany H, Sadek k, Kheir-Eldeen A. Antioxidant and Immunostimulant Effects of Basil (*Ocimum basilicum*) Against Gibberllic Acid and Auxin Supplemention in Broilers Ration. Global Veterinaria. 2015; 15: 289-295.
29. Gaikwad SB, Mohan DGK, Reddy KJ. Moringa oleifera leaves: Immunomodulation in wistar albino rats. Int. J. Pharm. Pharm. Sci. 2011; 3: 975-1491.
30. Fathiazad F, Matlobi A, Khorrami A, Hamedeyazdan S, Soraya H, Hammami M, et al. Phytochemical screening and evaluation of cardioprotective activity of ethanolic extract of *Ocimum basilicum L.* (basil) against isoproterenol induced myocardial infarction in rats. DARU Journal of pharmaceutical sciences. 2012; 20: 87.

31. Ojeka S, Obia O, Dapper D. Effect of Acute Administration of Aqueous Leaf Extract of Moringa oleifera on Immunoglobulin levels in Wistar Rats. European Journal of Medicinal Plants. 2016; 14.

32. Kushner I. Regulation of the acute phase response by cytokines. Perspectives in biology and medicine. 1993; 36: 611-622.

33. Duque GA, Descoteaux A. Macrophage cytokines: involvement in immunity and infectious diseases. Frontiers in immunology. 2014; 5: 491.

34. Weinstein DL, O'Neill BL, Metcalf ES. Salmonella typhi stimulation of human intestinal epithelial cells induces secretion of epithelial cell-derived interleukin-6. Infection and immunity. 1997; 65: 395-404.

35. Nakamura K, Mitarai Y, Yoshioka M, Koizumi N, Shibahara T, Nakajima Y. Serum levels of interleukin-6, alpha1-acid glycoprotein, and corticosterone in two-week-old chickens inoculated with *Escherichia coli* lipopolysaccharide. Poultry Science. 1998; 77: 908-911.

36. Rodrigues LB, Martins AOBPB, Cesário FRAS, e Castro FF, de Albuquerque TR, Fernandes MNM, et al. Anti-inflammatory and antiedematogenic activity of the *Ocimum basilicum* essential oil and its main compound estragole: *In vivo* mouse models. Chemico-Biological Interactions. 2016; 257: 14-25.

37. Adedapo AA, Falayi OO, Oyagbemi AA. Evaluation of the analgesic, anti-inflammatory, anti-oxidant, phytochemical and toxicological properties of the methanolic leaf extract of commercially processed Moringa oleifera in some laboratory animals. Journal of basic and clinical physiology and pharmacology. 2015; 26: 491-499.

38. Oyewo E, Adewale A, Abdulfatai A, Musbau A. Repeated oral administration of aqueous leaf extract of Moringa oleifera modulated immunoactivities in Wistar rats. J. Nat. Sci. Res. 2013; 3: 100-109.

39. Yadav NP, Khatri R, Bawankule DU, Pal A, Shanker K, Srivastava P, et al. Topical anti-inflammatory effects of *Ocimum basilicum* leaf extract in the phorbol-12,13-dibutyrate model of mouse ear inflammation. Planta Med. 2009; 75: PA72.

40. Przybylska J, Albera E, Kankofer M. Antioxidants in bovine colostrum. Reproduction in Domestic Animals. 2007; 42: 402-409.

41. Ciftci M, Simsek UG, Yuce A, Yilmaz O, Dalkilic B. Effects of dietary antibiotic and cinnamon oil supplementation on antioxidant enzyme activities, cholesterol levels and fatty acid compositions of serum and meat in broiler chickens. Acta Veterinaria Brno. 2010; 79: 33-40.

42. Yazar E, Er A, Uney K, Bulbul A, Avci GE, Elmas M, et al. Effects of drugs used in endotoxic shock on oxidative stress and organ damage markers. Free radical research. 2010; 44: 397-402.

43. Kono H, Asakawa M, Fujii H, Maki A, Amemiya H, Yamamoto M, et al. Edaravone, a novel free radical scavenger, prevents liver injury and mortality in rats administered endotoxin. Journal of pharmacology and experimental therapeutics. 2013; 307: 74-82.

44. Konukoglu D, Iynem H, Ziylan E. Antioxidant status in experimental peritonitis: effects of alpha tocopherol and taurolin. Pharmacological research. 1999; 39: 247-251.

45. Eslami H, Batavani RA, Asr S. Changes of stress oxidative enzymes in rat mammary tissue, blood and milk after experimental mastitis induced by *E. coli* lipopolysaccharide, In: Veterinary Research Forum. 2015; 6: p. 131.

46. Yazar E, Konyalioglu S, Col R, Birdane YO, Bas AL, Elmas M. Effects of vitamin E and prednisolone on some oxidative stress markers in endotoxemic rabbits. Revue Méd. Vét. 2004; 155: 538-542.

47. Birben E, Sahiner UM, Sackesen C, Erzurum S, Kalayci O. Oxidative stress and antioxidant defense. World Allergy Organization Journal. 2012; 5: 9-19.

48. Luqman S, Srivastava S, Kumar R, Maurya AK, Chanda D. Experimental assessment of Moringa oleifera leaf and fruit for its antistress, antioxidant, and scavenging potential using in vitro and *in vivo* assays. Evidence-Based Complementary and Alternative Medicine. 2012; 2012.

49. Kim H-J, Chen F, Wang X, Rajapakse NC. Effect of methyl jasmonate on secondary metabolites of *sweet basil* (*Ocimum basilicum L.*). Journal of Agricultural and Food Chemistry. 2016; 54: 2327-2332.

50. Wei A, Shibamoto T. Antioxidant/lipoxygenase inhibitory activities and chemical compositions of selected essential oils. Journal of agricultural and food chemistry. 2010; 58: 7218-7225.

51. Mahajan SG, Mali RG, Mehta AA. Effect of Moringa oleifera Lam. seed extract on toluene diisocyanate-induced immune-mediated inflammatory responses in rats. Journal of immunotoxicology. 2007; 4: 85-96.

52. Sakr SA, Al-Amoudi WM. Effect of leave extract of *Ocimum basilicum* on deltamethrin induced nephrotoxicity and oxidative stress in albino rats. Journal of Applied Pharmaceutical Science. 2012; 2: 22.

53. Allam H, Abdelazem AM, Salah H, Hamed A. Some hemato-biochemical, bacteriological and pathological effects of Moringa oleifera leaf extract in broiler chickens. International Journal of Basic and Applied Sciences. 2016; 5: 99-104.

54. Dho-Moulin M, Fairbrother JM. Avian pathogenic *Escherichia coli* (APEC). Veterinary research. 1999; 30: 299-316.

55. Manimaran K, Singh S, Shivachandra S. Haematobiochemical and pathological changes in experimental *Escherichia coli* infection in broiler chicks. Indian Journal of Animal Sciences Y. 2010; 73: 960-962.

56. Nakamura K, Yuasa N, Abe H, Narita M. Effect of infectious bursal disease virus on infections produced by *Escherichia coli* of high and low virulence in chickens. Avian Pathology. 1990; 19: 713-721.

57. Owolabi J, Ogunnaike P. Histological evaluation of the effects of Moringa leaf extract treatment on vital organs of murine models. Merit Research Journal of Medicine and Medical Sciences. 2014; 2: 245-257.

58. Lu W, Wang J, Zhang H, Wu S, Qi G. Evaluation of Moringa oleifera leaf in laying hens: effects on laying performance, egg quality, plasma biochemistry and organ histopathological indices. Italian Journal of Animal Science. 2016; 15: 658-665.

59. Kavoi BM, Gakuya DW, Mbugua PN, Kiama SG. Effects of dietary Moringa oleifera leaf meal supplementation on chicken intestinal structure and growth performance. J. Morphol. Sci. 2016; 33: 186-192.