SCIENCEFORECAST
Connecting Research to Drive Scientific Innovation

Review Article
Published: 28 May, 2018

SF Journal of Dentistry

Immediate Implant Placement: A Review

Amine M[2], El Kholti W[1], Laalou Y[3], Bennani A[2] and Kissa J[1]*

[1]Department of Periodontology, University of Hassan II of Casablanca, Morocco

[2]Department of Prosthdontics, University of Hassan II of Casablanca, Morocco

[3]Private Practice Casablanca, Morocco

Abstract

The concept of implant placement in fresh extraction sockets has emerged in recent years. Since then, it has seen substantial changes due to the better understanding of the healing phenomena of sockets after tooth extraction. The immediate implant placement technique is indicated in cases of perfect extraction's sockets. It provides very good long-term results. If there are bone defects prior or secondary to tooth extraction, bone regeneration is indicated. Initially limited to healthy sites, the indications of this procedure are expanded even to infected sites, with reduced periodontal support though with taking special precautions. The purpose of this article is to make an update on this topic and to pinpoint the technical factors that can significantly support optimal results.

Keywords: Tooth Extraction; Dental implant; Immediate; Surgery

Introduction

The success of an implant-supported restoration is related to the quality of the prosthetic restoration as well as its integration into the surrounding tissues. In cases of compromised teeth, the immediate implantation consists in placing an implant immediately into tooth extraction site. The major difficulty of obtaining a good result could be associated to the tissue's architectural modifications. These changes may occur even before extraction by loss of buccal and/or inter-proximal tissues resulting in gingival recession and/or loss of the inter-proximal papilla; or after dental extraction by bone resorption and remodeling. Immediate implantation after extraction is a commonly accepted and advantageous technique. But if certain fundamental principles are not respected, it can cause significant damage, sometimes irreversible. The aim of this article is to make an update on this topic and to pinpoint the technical factors that can significantly support optimal results.

Alveolar Socket Healing after Tooth Extraction

Dimensional changes of hard tissue

Araujo M et al, [1] described the normal alveolar socket healing in three phases:

- The inflammatory phase begins with the formation of the blood clot. During the 2-3 days following extraction, inflammatory cells migrate to the site to "clean" it before the formation of a new tissue. The combination of inflammatory cells, vascular sprouts and immature fibroblasts forms a granulation tissue after 4 to 5 days. Which is gradually replaced with provisional connective tissue matrix that is rich in collagen fibers and cells [1,2].

- The proliferative phase is characterized by an intense and rapid tissue formation. There is an appearance of osteoid calcification, which begins at the base and at the periphery of the socket. The bone matrix appears very early towards the second week of healing, and will be replaced by mature bone tissue [1]. Bone filling occurs between 5 to 10 weeks and it is complete after 16 weeks. A complete epithelial closure of the socket takes place after 4 to 5 weeks [2].

- Bone modeling and remodeling phase: Bone modeling is characterized by a change in the shape and architecture of the bone [1]. The healing process after tooth extraction is characterized by resorption, which can cause complications during the implant restoration [2,3]. When no ridge preservation procedure has been performed, a mean bone resorption of 1 to 2 mm in the vertical direction and 4 to 5 mm in the horizontal direction were observed [2]. Resorption is more important at the buccal than lingual or palatal aspect. It is more pronounced in the molar region, but it remains critical in the anterior region because of the aesthetic requirement [1]. The main bone resorption

OPEN ACCESS

*Correspondence:
Wafa El kholti, Department of Periodontology, University of Hassan II of Casablanca, Morocco.
Tel: +212677874671
Fax: +212522222749
E-mail: welkholti@gmail.com

Received Date: 10 Apr 2018
Accepted Date: 22 May 2018
Published Date: 28 May 2018

Citation: Amine M, El Kholti W, Laalou Y, Bennani A, Kissa J. Immediate Implant Placement: A Review. SF J Dent. 2018; 1(2): 1013.

ISSN 2643-7104

Copyright © 2018 El Kholti W. This is an open access article distributed under the Creative Commons Attribution License, which permits unrestricted use, distribution, and reproduction in any medium, provided the original work is properly cited.

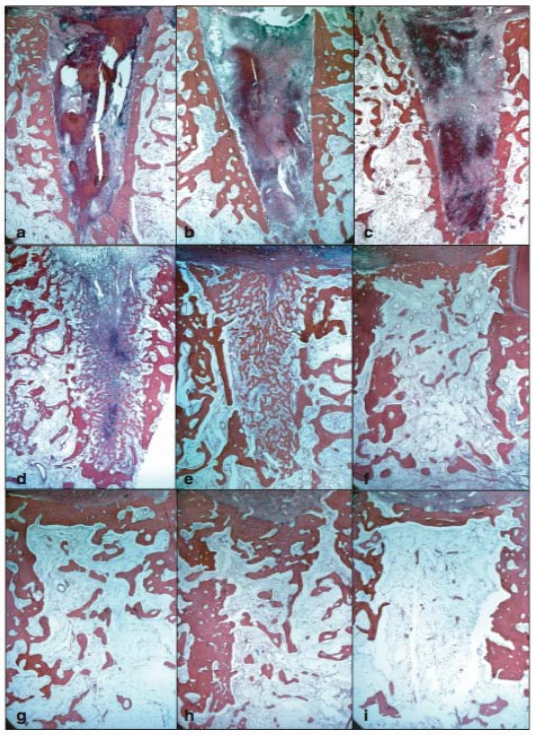

Figure 1: Mesio-distal sections illustrating the extraction socket after different intervals of healing: (a) 1 day, (b) 3 day, (c) 7 day, (d) 14 day, (e) 30 day, (f) 60 day, (g) 90 day, (h) 120 day, (i) 180 day. H&E staining; original magnification 16 [5].

occurred during the first year after extraction, of which 2/3 were observed during the first 3 months [4]. Regarding bone remodeling, no changes in the shape and architecture of the ridge are observed. It continues for several months or years [1,5] (Figure 1).

The ridge preservation immediately after extraction has a direct impact on the aesthetic and functional results of the prosthetic treatment. The goal is to maintain alveolar bone architecture, prevent soft tissue relapse and minimize or eliminate the need for bone augmentation procedures [4]. Januario et al [6], studied the characteristics of buccal bone wall in the anterior maxilla on 250 patients with healthy periodontium using CBCT (Cone Beam Computed Tomography). The authors concluded that dental sites at the anterior maxillary teeth have a thin buccal wall (less than 1mm), which may contribute to its loss after tooth extraction [6]. Partial or complete resorption of this wall will occur if no preservation technique will be used [2]. The socket filling may limit soft tissue shrinkage during healing and may provide support for bone formation [1,7]. Immediate implant placement does not prevent buccal bone loss. After extraction, the buccal bone wall resorption occurs even with immediate implantation [1]. Bone remodeling takes place during the healing phase which follows the immediate implant placement with resorption of the buccal and lingual bone walls at the implant site in the vertical and horizontal direction [8,9]. If Botticelli et al [10], have reported a mean bone gain of 0.2mm over 5 years. Numerous authors [11,12] noted a low bone resorption varying from 0.18 to 0.79 mm compared to the delayed implantation after 1 to 3 years of healing.

Dimensional changes of soft tissue

Mild gingival recession may be associated with immediate implant placement [13,14]. Regardless of the periodontal biotype, a soft tissue defect (width) is noted. If a soft tissue management was not performed, an apical relapse of the mucosa may occur which lead to the appearance of recession [14].

Indications

Immediate implantation is indicated in the cases of teeth compromised by dental trauma, root fractures/root fissures, endodontic complications, root resorptions. It is limited to sites with 3 or 4 alveolar walls with a minimum of circumferential defect. Most authors recommend the presence of at least 3 to 5 mm of residual bone beyond the apex and a minimum bone height of 10mm for primary implant stability [15].

Advantages [12,16]:

- Patient psychological advantages.
- Technical advantages: Bone of fresh extraction socket is dense, ridge shape is similar to the dental arch, reduced treatment duration, some additional techniques such as sinus lift or grafting could be avoided in some situations, soft tissue preservation by maintaining the inter-dental papilla.

Disadvantages [15,16]:

- Risk of partial resorption of alveolar wall (s) due to a pathologic process or to a traumatic damage during the extraction.
- Augmentation of the risk of infectious complications and failures.
- Difficulty to achieve a primary stability.
- Gap between implant surface and socket wall
- Additional cost in cases of combined guided bone regeneration
- Difficulty to predict the final position of the implant (case of multirooted teeth).
- Difficulty to achieve a complete closure of the implant site.
- Need to raise a flap in order to cover the implant if 2 stage-procedures is preferred.

The implant survival rate of immediate implantation is 96-100% [12,17]. It could be considered as a predictable and reliable procedure.

Key Elements in Immediate Implant Placement Surgery

- Delicate starting with a pilot drill; because of the hardness of the palatal wall, there is a risk to slip into the socket and perforate the buccal bone plate. To avoid this problem, two techniques have been proposed:

1. Round bur technique is indicated in cases of immediate implantation without or with minimal tissue loss. The drilling is initiated with a small round bur about 1/3 of the apex on the palatal wall of the socket. The drilling is then carried out keeping a palatal direction with respect to the tooth axis. However, it would be not possible to recover the bone and it must be completed by a grafting material in cases of residual space greater than 2mm.

2. The trepan technique allows better axis implant control with recovery of the bone for further filling (Figure 2).



Figure 2: Immediate implant placement technique:
a: Bur round technique: a1: Trepanation using a bur round; a2: Implant drilling; a3: Implant placement.
b: Trepan technique: b1,b2: Bone graft harvesting using a trepan; b3: Implant drilling; b4: Implant placement; b5: Bone graft placement between the implant and buccal bone socket.

- During implant site preparation, the drilling should extend beyond the socket to optimize the implant primary stability. In the cases of an apical lesion, drilling should be performed beyond this lesion in order to remove infected tissue and to achieve a reliable anchorage in the healthy tissue.
- Choice of an implant of an adequate diameter according to the anatomical and prosthetic requirements.
- A 3-4 mm horizontal distance between the adjacent implant/tooth and a 3-5 mm vertical distance between contact point/inter-proximal bone are significantly associated with a complete inter-dental papilla fill [18] (Figure 3).
- The implant axis rarely follows the socket axis:
  - At the upper-anterior region, the implant is placed more palatal than the extraction socket, for the upper molars and premolars with 2 roots, it is placed at the level of the septum.
  - At the lower molars region, the implant is placed at the inter-radicular septum.
  - For the lower-anterior region, implants are as parallel as possible.

What are the Risk Factors?

Cause of extraction

Weakened Periodontal support: Immediate implantation in patients with severe periodontitis involves a higher risk of failure [19]. The implant survival rate in the case of immediate implantation on periodontally compromised teeth varies between 84 and 98.4% with a significant difference with healed sites [12,16].

Chronic peri-apical infection: Chronic peri-apical infection is not an absolute contra-indication to immediate implantation if debridement precautions and careful cleaning of the socket are taken into account. The risks of failure are similar to the immediate implant placement in the absence of apical pathology [11].

Periodontal biotype

Mucosal recession is a common observation in several studies with immediate implants [20,21]. Based on the literature, a risk of 20–30% for a buccal mucosal recession of more than 1mm was reported. A thin periodontal biotype may be considered as a risk factor for the development of this mucogingival defect [21]. Gingival augmentation may improve the periodontal biotype and peri-implant health [22].

Extraction socket

A careful evaluation of the implantation site before extraction could promote the aesthetic results [23]. Juodzbalys et al [24] concluded that immediate implantation is successful in a limited number of ideal extraction socket cases. On the other hand, in cases of compromised socket, the aesthetic results of immediate implantation are unpredictable. Predictable aesthetic results are observed with delayed implantation associated with guided bone regeneration and tissue grafting [24].

Implant macro and micro design

The smooth machined implant surface would be twice as likely to fail as a rough implant surface [15]. Artzi et al [25] associated failure to short (8mm) and narrow (3.3mm) implants. Regarding the configuration of the implant (cylinder, screw), Sanz et al [26] suggested that it would not influence the dimensions of the gap between the implant surface and the socket wall [26]. Primary stability would be critical in terms of osseointegration in cases of immediate implantation [13,23].

Gap implant/socket walls, guided bone regeneration

According to Matarasso et al. [19], the initial bone wall thickness before the immediate implantation associated with guided bone regeneration may influence bone formation. Intra-bony defects are partially or completely remodeled (healed) without further intervention [27]. A lateral gap of 1 to 1.25 mm could heal spontaneously with formation of a new bone; the addition of a membrane would not improve the healing process [27]. In cases of an important defect, the choice is made between an immediate implantation associated with guided bone regeneration or a delayed implantation. The decision criteria for the surgeon are related to the possibility of complete site closure (hermetic sutures). If this latter was not obtained, the risk of membrane exposure may lead to graft complications and implant failure [12]. According to Araujo et al [28], the filling of the gap remained between the implant and the buccal bone plate with autogenous bone graft could be resorbed [28]. Bovine hydroxyapatite material could reduce bone resorption in the buccal aspect of the implant [15]. Partial bone formation occurs when space is filled by Beta-TCP [29]. However, no scientific evidence of superiority of one material over another has been yet established [29]. Animal experiments with injection of mesenchymal cells of the umbilical cord in the case of a severe peri-implant bone defect have shown their ability to promote formation of new bone [30].

Abutment

Data from the literature reported a gain in peri-implant mucosa and papillary height in immediate implantation cases with platform

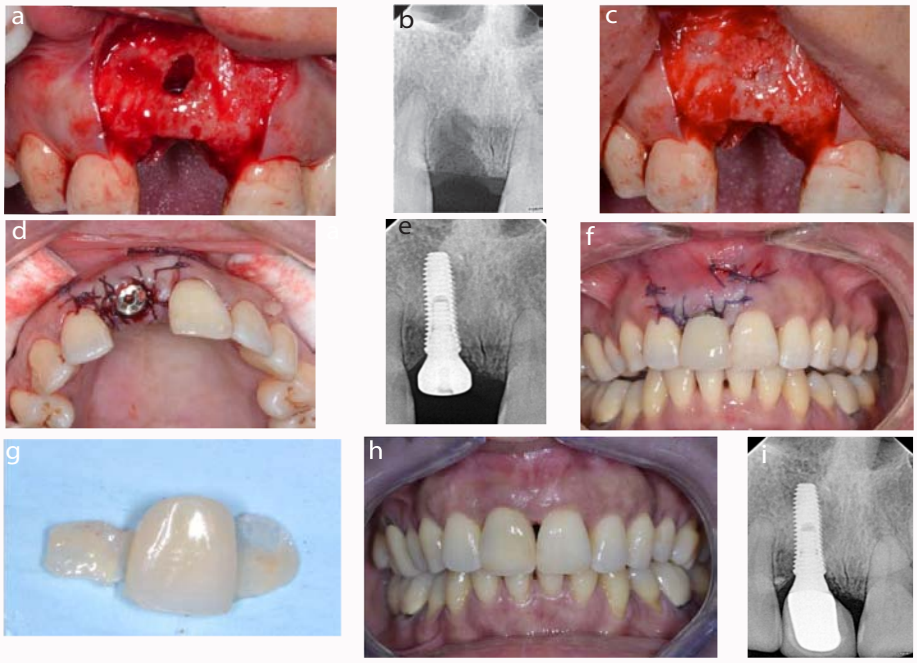

Figure 3: Immediate implant placement associated with bone fenestration.
a,b,c,d: Extraction of root 11, immediate implantation and filling of buccal fenestration with an autogenous bone graft obtained from drilling.
e: Post-operative radiograph.
f,g: Provisionalisation with bonded fixed partial denture.
h: Final prosthesis.
i: Control radiograph 6 months after final prosthesis.

switching [31]. On the other hand, a randomized prospective clinical study by Pieri et al [11] revealed no significant difference in periodontal parameters, soft tissue changes and papillary height between cases of immediate implantation associated with morse taper abutment and platform switching and the cases of immediate implantation associated with an internal connection abutment and platform matching at 12 months of follow-up.

Post-operative medication

Patients who are unable to take a post-operative amoxicillin could be three times more likely to be at risk of failure than those taking amoxicillin-based antibiotic coverage [15].

Provisionalisation, loading

Artzi et al. [25] found a more pronounced bone resorption in cases of immediate implantation associated with immediate loading compared to delayed implantation in a healed site associated with immediate loading. However, the combination of immediate implantation with immediate loading would have a cumulative survival rate of 100% at 24 months with no difference in bone resorption compared to immediate implantation with delayed loading [32] and compared to traditional protocols [33]. Numerous authors [27,34] concluded that the immediate implantation associated with provisionalisation without functional loading could be considered as a therapeutic option in cases of anterior single tooth replacement.

Conclusion

Immediate implant placement is a reliable technique with implant success rates comparable to those obtained by conventional protocol. It allows a significant comfort to the patient, a reduction of the healing duration and a preservation of the gingival architecture; which optimizes the aesthetic outcomes. Clinical parameters and case selection would be taken into account to increase the predictability to achieve successful results.

References

1. Araùjo MG, Silva CO, Misawa M, Sukekava F. Alveolar socket healing: what can we learn? Periodontology 2000. 2015; 68: 122-134.
2. Al Sabbagh M, Kutkut A. Immediate implant placement: Surgical techniques for prevention and management of complications. Dent Clin Am. 2015; 59: 73-95.
3. Araùjo MG, Lindhe J. Dimensional ridge alterations following tooth extraction. An experimental study in the dog. Journal of Clinical Periodontology. 2005; 32: 212–218.
4. Schropp L, Wenzel A, Kostopoulos L, Karring T. Bone healing and soft tissue contour changes following single-tooth extraction: a clinical and radiographic 12-month prospective study. Int J Perio Rest Dent. 2003; 23: 313-323.
5. Cardaropoli G, Arau´ jo M, Lindhe J. Dynamics of bone tissue formation in tooth extraction sites: An experimental study in dogs. J Clin Periodontol. 2003; 30: 809–818.
6. Janario AL, Duarte WR, Barriviera M, Mesti JC, Araujo MG, Lindhe J. Dimension of the facial bone wall in the anterior maxilla: a cone beam computed tomography study. Clin Oral Impl Res. 2011: 10: 1168-1171.
7. Cardaropoli D, Gaveglio L, Gherlone E, Cardaropoli G. Soft Tissue Contour Changes at Immediate Implants: A Randomized Controlled Clinical Study. Int J Periodontics Restorative Dent. 2014; 34: 631–637.
8. Araujo MG, Sukekava F, Wennstrom JL, Lindhe J. Ridge alterations following implant placement in fresh extraction sockets: an experimental study in the dog. J. Clin. Periodontol. 2005; 32: 645-652.
9. Botticelli D, Bergiundh T, Lindhe J. Hard tissue alterations following immediate implant placement in extraction sites. J. Clin. Periodontol. 2004; 31: 820-828.

10. Botticelli D, Renzi A, Lindhe J, Berglundh T. Implants in fresh extraction sockets: a prospective 5-year follow-up clinical study. Clin Oral Implants Res. 2008; 19: 1226-1232.

11. Pieri F, Aldini N, Marchetti C, Corinaldesi G. Influence of implant-abutment interface design on bone and soft tissue levels around immediately placed and restored single tooth implants: a randomized controlled clinical trial. Int J Oral Maxillofac Implants. 2011; 26: 169-178.

12. Schropp L, Isidor F. Timing of implant placement relative to tooth extraction. J Oral Rehabil. 2008; 35: 33-43.

13. Canullo L, Iurlaro G, Iannello G. Double-blind randomized controlled trial study on post-extraction immediately restored implants using the switching platform concept: soft tissue response. Preliminary report. Clin Oral Implants Res. 2009; 20: 414-420.

14. Van Kesteren CJ, Schoolfield J, West J, Oates T. A prospective randomized clinical study of changes in soft tissue position following immediate and delayed implant placement. Int J Oral Maxillofac Implants. 2010; 25: 562-570.

15. Bhola M, Neely AL, Kolhatkar S. Immediate implant placement: clinical decisions, advantages, and disadvantages. J Prosthodont. 2008; 17: 576-581.

16. Esposito M, Grusovin MG, Polyzos IP, Felice P, Worthington HV. Timing of implant placement after tooth extraction: immediate, immediate-delayed or delayed implants? A Cochrane systematic review. Eur J Oral Implantol. 2010; 3: 189-205.

17. Cardaropoli D, Tamagnone L, Roffredo A, Gaveglio L. Evaluation of dental implants placed in preserved and non preserved post extraction ridges: A 12 month post loading study. Int J Periodontics Restorative Dent. 2015; 35: 677-685.

18. Jaffin R, Kolesar M, Kumar A, Ishikawa S, Fiorellini J. The radiographic bone loss pattern adjacent to immediately placed, immediately loaded implants. Int J Oral Maxillofac Implants. 2007; 22: 187-194.

19. Matarasso S, Salvi GE, Iorio Siciliano V, Cafiero C, Blasi A, Lang NP. Dimensional ridge alterations following immediate implant placement in molar extraction sites: a six-month prospective cohort study with surgical re-entry. Clin Oral Implants Res. 2009; 20: 1092-1098.

20. Buser D, Chappuis V, Belser U, Chen S. Implant placement post extraction in esthetic single tooth sites: when immediate, when early, when late? Periodontol 2000. 2017; 73: 84–102.

21. Kan JY, Rungcharassaeng K, Sclar A, Lozada JL. Effects of the facial osseous defect morphology on gingival dynamics after immediate tooth replacement and guided bone regeneration: 1-year results. J Oral Maxillofac Surg. 2007; 65: 13–19.

22. Kissa J, El Kholti W, Laalou Y, El Farouki M. Augmentation of keratinized gingiva around dental implants. J Stomatol Oral Maxillofac Surg. 2017; 118: 156-160.

23. Crespi R, Capparé P, Gherlone E, Romanos GE. Immediate versus delayed loading of dental implants placed in fresh extraction sockets in the maxillary esthetic zone: a clinical comparative study. Int J Oral Maxillofac Implants. 2008; 23: 753-758.

24. Juodzbalys G, Wang HL. Soft and hard tissue assessment of immediate implant placement: a case series. Clin Oral Implants Res. 2007; 18: 237-243.

25. Artzi Z, Kohen J, Carmeli G, Karmon B, Lor A, Ormianer Z. The efficacy of full-arch immediately restored implant-supported reconstructions in extraction and healed sites: a 36-month retrospective evaluation. Int J Oral Maxillofac Implants. 2010; 25: 329-335.

26. Sanz M, Cecchinato D, Ferrus J, Pjetursson EB, Lang NP, Lindhe J. A prospective, randomized-controlled clinical trial to evaluate bone preservation using implants with different geometry placed into extraction sockets in the maxilla. Clin Oral Implants Res. 2010; 21: 13-21.

27. Siciliano VI, Salvi GE, Matarasso S, Cafiero C, Blasi A, Lang NP. Soft tissues healing at immediate transmucosal implants placed into molar extraction sites with buccal self-contained dehiscences. A 12-month controlled clinical trial. Clin Oral Implants Res. 2009; 20: 482-488.

28. Araujo MG, Lindhe J. Socket grafting with the use of autologous bone: an experimental study in the dog. Clin. Oral. Impl. Res. 2011; 22: 9-13.

29. Alves CC, Correia AR, Neves M. Immediate implants and immediate loading in periodontally compromised patients-a 3-year prospective clinical study. Int J Periodontics Restorative Dent. 2010; 30: 447-455.

30. Deng F, Zhang H, Zhang H, Shao H, He Q, Zhang P. A comparison of clinical outcomes for implants placed in fresh extraction sockets versus healed sites in periodontally compromised patients: a 1-year follow-up report. Int J Oral Maxillofac Implants. 2010; 25: 1036-1040.

31. Chang SW, Shin SY, Hong JR, Yang SM, Yoo HM, Park DS, et al. Immediate implant placement into infected and noninfected extraction sockets: a pilot study. Oral Surg Oral Med Oral Pathol Oral Radiol Endod. 2009; 107: 197-203.

32. Tarazona B, Tarazona-Alvarez P, Penarrocha-Oltra D, Penarrocha-Diago M. Relationship between indication for tooth extraction and outcome of immediate implants: a retrospective study with 5 years of follow-up. J Clin Exp dent. 2014; 6: e 384-388.

33. Chang SW, Shin SY, Hong JR, Yang SM, Yoo HM, Park DS, et al. Immediate implant placement into infected and noninfected extraction sockets: a pilot study. Oral Surg Oral Med Oral Pathol Oral Radiol Endod. 2009; 107: 197-203.

34. Crespi R, Capparé P, Gherlone E, Romanos GE. Immediate versus delayed loading of dental implants placed in fresh extraction sockets in the maxillary esthetic zone: a clinical comparative study. Int J Oral Maxillofac Implants. 2008; 23: 753-758.