SCIENCEFORECAST
Connecting Research to Drive Scientific Innovation
Published: 10 Sep, 2018

SF Journal of Dermatology

Pemphigus in North-Western Yemen: A Clinicoepidemiologic Study of 75 Cases

*Khatri ML**

Department of Dermatology, Saudi Hospital at Hajjah, Republic of Yemen

Abstract

Objective: Incidence of pemphigus seems to be quite high in Yemen but not documented. The present work is aimed to study the clinicoepidemiologic profile of pemphigus in northwestern Yemen.

Methods: All 75 patients (39 males and 36 females) diagnosed at Saudi Hospital, Hajjah, Republic of Yemen, between January 1997 and December 2013 were subjected to detailed analysis. Diagnosis was based on clinical features, histopathology, and Tzank test. Immunofluorescence was not available. Ethical approval was obtained from the responsible hospital authority.

Results: Incidence of pemphigus cases among new dermatology patients in our department was 0.101%. All patients were Yemeni nationals originated from 11 governorates of northwestern Yemen. Although family history of pemphigus was not available in most of the cases but 4 patients from Yarim village (Ibb Governorate) were related to each other. The types of pemphigus diagnosed were pemphigus vulgaris (PV) in 46, pemphigus foliaceus (PF) in 23, pemphigus vegetans (PVEG) in 5, and pemphigus herpatiformis (PH) in 1 patent. Four patients of PF developed erythroderma, one patent of PVEG had vegetative lesions on eyelid margins and one childhood PV case had unusual initial presentation like TEN.

Conclusion: The incidence of pemphigus seems to be quite high in northwestern region of Yemen with maximum cases of PV.

Keywords: Northwestern Yemen; Pemphigus vulgaris; Pemphigus foliaceus; Pemphigus vegetans; Pemphigus herpatiformis

OPEN ACCESS

Correspondence:
Mishri Lal Khatri, Snr. Consultant – Dermatology, Medipulse Hospital, Jodhpur, India.
Tel: *+917568769382*
E-mail: *mishrik1@yahoo.co.in*

Received Date: *17 Jul 2018*
Accepted Date: *04 Sep 2018*
Published Date: *10 Sep 2018*

Citation: *Khatri ML. Pemphigus in North-Western Yemen: A Clinicoepidemiologic Study of 75 Cases. SF J Dermatol. 2018; 1(2): 1010.*

Copyright *© 2018 Khatri ML. This is an open access article distributed under the Creative Commons Attribution License, which permits unrestricted use, distribution, and reproduction in any medium, provided the original work is properly cited.*

Introduction

Pemphigus is a group of autoimmune blistering diseases, mediated by antibodies directed against desmosomal adhesion proteins (most particularly desmogleins 1 and 3) that are responsible for maintaining integrity of the epidermis [1,2], varying in clinical features and incidence in various population groups [3]. All ages can be affected by pemphigus, though it is most common in middle age, and both sexes are affected equally. A rare endemic form of pemphigus foliaceus (fogo selvagem) has been identified in parts of Brazil and in North Africa [3,4].

The genetics of pemphigus are complex. Familial cases are uncommon but there are strong associations with certain genes in the MHC complex which vary according to the population studied. Thus, in Jewish populations DRB1*0402 is highly over expressed whereas this is less common in Western Europeans. Conversely, the DRB1*1401 allele is highly over expressed in European and Japanese groups. Interestingly, genetic polymorphisms have recently been identified in the desmoglien 3 antibody target gene that associate with the disease and are in epistasis with the MHC associations [5].

The primary pathogenic event in all forms of pemphigus is acantholysis, the separation of epidermal keratinocytes from each other. This leads to blister formation within the epidermis and is a key histological diagnostic feature of the disease [6].

Antibodies develop against various elements of the desmosomes, particularly desmogleins 1 and 3. Desmoglein 1 is found particularly in the superficial layers of the epidermis; antibodies against this protein alone result in pemphigus foliaceus. Desmoglien 3 is more widely distributed in the lower parts of the epidermis and in mucosal epithelia. Thus, antibodies against this protein are associated with pemphigus vulgaris, typically presenting with mucosal ulceration. Tissue-bound antibodies (generally immunoglobulin (IgG but rarely IgA) and complement can be detected

Figure 1: Geographical distribution of pemphigus cases in north-western Yemen.

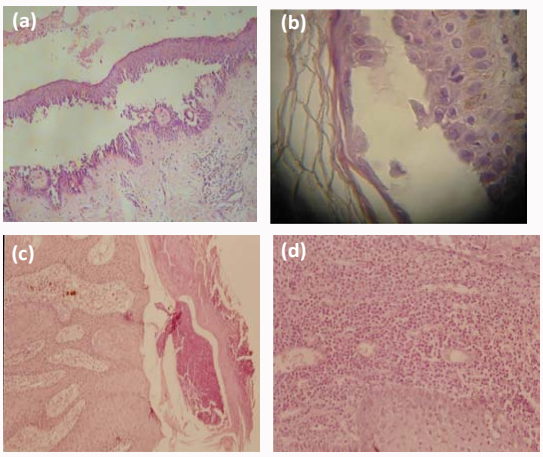

Figure 2: (a) Histopathologic features of PV, showing suprabasal vesicle with acantholytic cells. Hematoxylin – eosin stain; original magnification: x 40. (b) Histopathologic features of PF, showing subcornial vesicle with acantholytic cells. Hematoxylin – eosin stain; original magnification: x 100. (c) Histopathologic features of PVEG, showing verrucous epidermal hyperplasia with papilomatosis and a suprabasal split on left side with few acantholytic cells. Hematoxylin – eosin stain; original magnification: x 40. (d) Histopathologic features of PVEG, showing eosinophilic abscess. Hematoxylin – eosin stain; original magnification: x 100.

by direct immunofluorescence of skin biopsy tissue. Circulating antibodies are detected by indirect immunofluorescence using skin or mucosal tissue substrates. More recently, specific ELISAs have become available for measurement of individual antidesmoglien antibody levels. Titers of antibodies tend to correlate with severity of disease [7]. Recent studies have revealed that acantholysis can also occur in presence of antibodies against 9-a nicotinic acetyl choline receptor [8]. Apoptosis of keratinocytes may also have a possible role in pathogenesis [9].

Pemphigus occurs in a number of clinical forms, each characterized by a distinct profile of auto antibodies. Different clinical forms are pemphigus vulgaris, pemphigus vegetans, pemphigus foliaceus, pemphigus erythematosus, pemphigus herpetiformis [4], Iga Pemphigus [10] and paraneoplastic pemphigus [11].

This is a prospective study of 75 cases of pemphigus seen at Saudi Hospital at Hajjah, Republic of Yemen between January1997 and December 2013. This hospital is run by Government of Saudi Arabia for the welfare of Yemeni people and all services are free including the supply of drugs.

Patients and Methods

This is a prospective study of clinicoepidemiologic aspect of 75 cases of pemphigus seen at the Department of Dermatology of Saudi Hospital at Hajjah, Republic of Yemen between January 1997 and December 2013. Ethical approval was obtained from the responsible hospital authority.

All the patients were admitted for the initial assessment and some of them were re-admitted with recurrence of the disease. Details of history (including geographic history and menstrual and obstetric history in all female patients), physical findings, laboratory data, treatment, and follow-up were recorded in a standardized protocol. The diagnosis was based on clinical features, histopathology and Tzank test. Punch (6mm) biopsies were taken from new representative lesions in all the cases, processed and stained with hematoxilin – eosin stain. Immunofluorescence was not available at our hospital and also at any other center in the country.

All the patients were also screened for pulmonary tuberculosis, diabetes, hypertension, cardiac disease and other autoimmune diseases.

Results

Incidence of pemphigus cases among new dermatology patients in our department was 0.101%. All 75 patients (male 39 and female 36) were Yemeni nationals coming from different regions of North Western Yemen. Governorate wise distribution of cases was: Hajjah 28, Hudayda 21, Ibb 7, Damar 4, Sana'a 3, Amran 3, Marib 3, Sadah 2, Mahveet 2, Taiz 1 and Aljauf 1 (Figure 1). Although family history of pemphigus was not available in most of the cases but 4 patients from Yarim village (Ibb Governorate) were related to each other. The age at onset of the disease ranged between 10 years and 85 years (median age 39.5 years). The duration of the disease at first presentation ranged between 3 weeks to 7 years (median duration 1 year). The onset of the disease process was gradual in 69 and acute in 6 patients. The disease was asymptomatic in 60 patients but 15 patients complained of mild to moderate pruritus.

Initial lesions noticed were vesiculobullous in 28, erosive in 23, both types in 22, big TEN type lesions in 1 (Figure 3e) and greasy scaly lesions with vegetative lesions in 1 patient 9 Figure 4d and 4e). Sites of initial lesions were mouth in 50 (Figure 3b), trunk in 15, face in 5, face and trunk in 3, mouth and trunk both in 1, axila and groins in 1 patient.

Nature of the lesions observed during the course of the disease was vesiculobullous in all (tense in 4 flaccid in 70 and grouped in 1, with erythematous base in 10 and without erythematous base in 65), erosions in 73, crusted erosions in 40 (Figure 3a), vegetative in 10 (Figure 4), pustular lesions in 42 patients, and erythroderma in 4 patients (Figure 5).

Distribution of the lesions observed during the course of the disease was: scalp in 47, face in 62, trunk in 72, arms in 44, legs in 50, axilla in 50, groins in 46, mouth in 51, genital mucosa in 18 (Figure 3c), nasal mucosa in 9 and conjunctivae in 8 patients (Figure 3d).

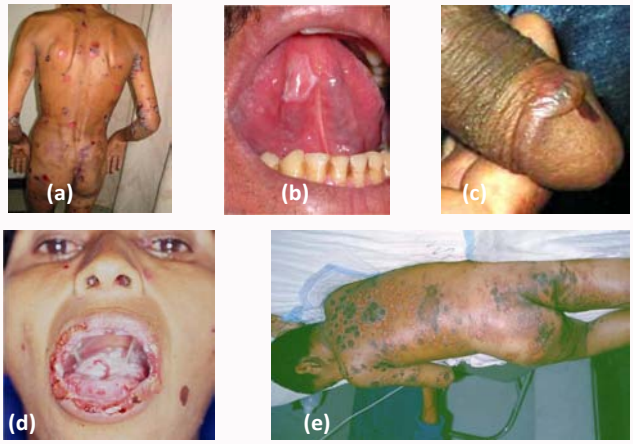

Figure 3: (a) A case of PV, showing multiple erosive and crusted body lesions. (b) Oral lesions of PV of patient in figure 3a. (c) Penile lesions of PV of patient in figure 3a. (d) A case of PV, showing eye, nasal mucosa and oral lesions with secondary candidiasis. (e) PV in a 10 year old boy initially presented with TEN like lesions.

Figure 4: (a) A case of PVEG with vegetative lesions on eyelid margins, nasal mucosa and lip margins. (b) A case of PVEG with vegetative lesions superadded with pustules. (c) A case of PVEG with vegetative lesions superadded with pustules and scaling on pubic region and lower abdomen. (d) A case of PVEG with thick vegetative lesions of lips. (e) Thick vegetative lesions in groins of patient in figure 4d.

Histopathology

Most of the biopsies revealed intraepidermal suprabasal vesicle formation with acantholytic cells (rounded keratinocytes with enlarged nucleus and dense cytoplasm) within the cavity. Few neutrophils were also seen. In the dermis mild perivascular infiltration was observed with few neutrophils and occasionally few eosinophils. These cases were diagnosed as pemphigus vulgaris (Figure 2a). In some cases the vesicles were seen in sub corneal region or within the granular cell layer, with acantholytic cells and few neutrophils. These cases were diagnosed as pemphigus foliaceus (Figure 2b). In cases with vegetative lesions, two biopsies were taken, one from the vesicular lesion and other from the vegetative lesion. In the vesicular lesions changes similar to that of pemphigus vulgaris were seen. The biopsies from the vegetative lesions revealed verrucous epidermal hyperplasia with aggregation of eosinophils within the epidermis and dermis forming eosinophilic spongiosis and eosinophilic pustules. These cases were diagnosed as pemphigus vegetans (Figure 2c and 2d). The biopsy from the patient with grouped lesions revealed intra epidermal vesicles filled with neutrophils, eosinophils and few acantholytic cells. This case was diagnosed as pempigus herpetiformis.

Figure 5: (a) A case of PF with generalized lesions, almost erythrodermic. (b) A case of PF with generalized lesions, almost erythrodermic. (c) 18 Cases of PF with erythrodermic changes.

On the basis of clinical features and histopathologic findings the cases were divided in following sub-types:

Pemphigus vulgaris (PV)	46 (M 22, F 24) 61.3%
Pemphigus foliaceus (PF)	23 (M 14, F 9) 30.6%
Pemphigus vegetans (P VEG)	5 (M 2, F 3) 6.6%
Pemphigus herpetiformis (PH)	1 (M) 1.3%

According to the extent of involvement and severity of symptoms the cases were classified as mild 4, moderate 13, severe 38 and extensive 20. Other associated diseases at the time of first presentation were diabetes mellitus in 3, hypertension in 3, endogenous eczema in 1, hydated cyst of the liver in 1, and history of treated (controlled) pulmonary tuberculosis in 1 patient.

Discussion

Although we could not estimate the exact incidence of pemphigus in Yemen, it seems to be quite high. Incidence among new dermatology patients in our department was 0.101%. Worldwide the incidence of pemphigus varies between 0.76 and 17 new cases per million of population per year [3]. The incidence of pemphigus in the adjacent Southern region of Saudi Arabia has been reported as 0.16 per 100000 [12]. A High incidence has been documented in Mediterranean population particularly in Jewish race [13], Tunis [14], Libya [15], Iran [16] and certain regions of India [17]. A higher incidence has also been reported in Tehran (1.6/100,000) [16]. In India the incidence of pemphigus cases among Dermatology patients varied from 0.09% to 1.08% [17] and the incidence assessed in Trisur district in Kerala was 4.4 per million [18]. Male female ratio in our patients is 1; 0.92 while in the Saudi cases it was 2.2:1 [12]. Female preponderance has been

reported in Kuwait (F/M::2:1.1) [19] Iran (F/M::1.5:1) [16], and Libya (F/M::4.7:1) [15]. In Libyan study 84% of the PF patients were female [15]. In general the age of onset was almost similar in the Saudi cases (40 year) [12], Iran (42 Year) [16], and Kuwait (36.4 years) [19]. Age of onset in two of our PV patients was 10 and 11 years and in third with PF was 10 years. Childhood cases of PV have also been reported from India [20,21] and some other countries[22]. Lower age of onset in cases of PF is reported from Tunis [14] Libya [15] and Brazil [23].

PV was the most common type of pemphigus in this series followed by PF and then PVEG. Almost similar ratio of different types has been reported from most of the countries [12,13,16,17,19] but the percentage of PF was very high in Tunis [14] and Libya [15]. Oral lesions preceded in all cases of PV and PVEG except one patient of PV in whom the oral and body lesions started simultaneously. One of the patients of PV had only oral lesions for one year and later she developed only few body lesions. Pemphigus vulgaris with exclusive oral lesions has also been reported in the past [24,25]. In addition to oral lesions a good number of our patients of PV and PVEG were also having involvement of nasal mucosa, conjunctiva and genital mucosa. Vulvo-cervico-vaginal lesions [26] and penile lesions [27] have also been reported in the past. One of our patients of PV aged 10 years initially presented with lesions similar to TEN and other patient of PVEG had vegetative lesions on eye lid margins. Such lesions have not been reported before to our knowledge. The percentage of erythroderma in PF cases was also quite high. Similar high percentage of erythroderma in PF has also been reported from Libya[15]. Other lesions in different types of pemphigus were similar to those reported from most of the countries [12,13,16,17,19].

Association of thymoma, myasthenia gravis, lupus erythematosus, carcinoma and lymphoproliferative diseases can coexist in cases of pemphigus [28]. In our patients the association of diabetes, hypertension, endogenous eczema and hydated cyst of the liver seems to be coincidental.

Conclusion

To conclude, the incidence of pemphigus seems to be quite high in northwestern region of Yemen with maximum cases of PV, higher incidence of erythroderma in PF, unusual initial presentation like TEN in a childhood PV case and vegetative lesions on eyelid margins in a case of PVEG.

References

1. Amagi M, Tsunoda K, Zillikens D, Nagai T, Nishikawa. The clinical phenotype of pemphigus is defined by the anti desmoglein anti body profile. J Am Acad Dermatol. 1999; 40: 167-170.
2. Jamora MJJ, Jiao D, Bystryn JC. Antibodies to desmogleins 1 and 3 and the clinical phenotype of pemphigus vulgaris. J am Acad Dermatol. 2003; 48: 976-977.
3. Meyer N, Misery L. Geoepidemiologic condiserations of auto-immune pemphigus. Autoimmunity Reviews. 2010; 9: A379-A382.
4. Joly P, Litrowski N. Pemphigus group (Vulgaris, vegetans, foliaceus, herpetiformis, braziliensis). Clinics in Dermatology. 2011; 29: 432-436.
5. Tron F, Gilbert D, Mouquet H, Joli P, Drout L, Makni S, et al. Genetic factors in pemphigus. J of Autoimmunity. 2005; 24: 319-328.
6. Rados J. Autoimmune blistering diseases: Histologic meaning. Clinics in Dermatology. 2011; 29: 377- 388.
7. Amagi M, Komai A, Hashimoto T, Shirakata Y, Hashimoto K, Yamada T, et al. Usefulness of enzyme linked immunosorbent assay using recombinant desmoglein 1 and 3 for serodiagnosis of pemphigus. Br. J Dermatol. 1999; 140: 351-357.
8. Grando SA. Pemphigus in 21st century. New life to an old story. Autoimmunity. 2006; 39: 521-530.
9. Scnidt E, Wasche J. Appoptosis in pemphigus. Autoimmunity Rev. 2009; 8: 533-537.
10. Tsuruta D, Ishii N, Hamada T, Ohyama B. Fukuda S, Koga H, et al. IgA pemphigus. Clinics in Dermatology. 2011; 29: 437-442.
11. Billet SE, Grando SA, Pittelkow MR. Paraneoplastic autoimmune multi organ syndrome; Review of literature and support for cytotoxic role in pathogenesis. Autoimmunity. 2006; 36: 617-630.
12. Tallab T, Joharji H, Bahamdan K, Karashan E, Murad M, Ibrahim K. Incidence of pemphigus in the Southern region of Saudi Arabia. Int J Dermatol. 2001; 40: 570-572.
13. Pisanti S, Sharav Y, Kaufman E, Posner LN. Pemphigus vulgaris: Incidence in Jews of different ethnic groups according to age, sex and initial lesions. Oral Surg Oral Med Oral Path. 1974; 38: 382-387.
14. Bastuji-Garin S, Souissi R, Blum L, Turki H, Nouira R, Jomaa B, et al. Comparative epidemiology of pemphigus between Tunisia and France: unusual incidence of pemphigus foliaceus in young Tunisian women. J Invest Dermatol. 1995; 104:302–305.
15. Shafi M, Khatri ML, Mashina M, Ben-Ghazeil M. A clinical study of 109 cases from Tripoli, Libya. Ind J Dermatol Venereol Leprol. 1994; 60: 140-143.
16. Chams-Davatchi C, Valikhani M, Daneshpazhooh M, Esmaili C ,Balighi K, Hallaji Z, et al. Pemphigus: Analysis of 1209 cases. Int J Dermatol. 2005; 44: 470-476.
17. Kanwar AJ, De D. Pemphigus in India. Ind J Dermatol Venereol Leprol. 2011; 77: 439-449.
18. Ajithkumar K. Incidence of pemphigus in Thrissur district, South India. Indian J Dermatol Venereol Leprol. 2008; 74: 349-351.
19. AlSaleh QA, Nanda A, AlBaghli NM, Dvorak R. Pemphigus in Kuwait. Int J Dermatol. 1999; 38: 351-356.
20. Kanwar AJ, Kaur S. Pemphigus in children. Int J Dermatol. 1991; 30: 343-346.
21. Kanwar AJ, Dhar S, Kaur S. Further experience with pemphigus in children. Pediatric Dermatol. 1994, 11: 107-111.
22. Bjarnason B, Flosadottir E. Childhood, neonatal, and stillborn pemphigus. Int J Dermatol. 1999; 38: 680-688.
23. Azulay RD. Brazilian pemphigus foliaceus. Int J Dermatol. 1982; 21: 122-124.
24. Mahajan VK, Sharma NL, Sharma RC. Twelve-year clinico-therapeutic experience in pemphigus: A retrospective study of 54 cases. Int J Dermatol. 2005; 44: 821-827.
25. Abdolsamadi HR, Abdollazade S, Vaziri PB, Baheshi A, Shafigh E, Vahedi M. Epidemiology of pemphigus in Tehran, Iran: A 20 year retrospective study. J Dental Research, Dental Clinics, Dental Prospects. 2007; 1:108-113.
26. Fairbanks Barbosa ND, Aguiar LM, Maruta CW, Aoki V, Scotto MN, Labinas GH, et al. Vulvo-cervico-vaginal manifestations and evaluation of papanicolaou smears in pemphigus vulgaris and pemphigus foliaceus. J Am acad Dermatol. 2012; 67: 409-416.
27. Sami N, Ahmed AR. Penile pemphigus. Arch Dermatol. 2001; 137: 756-758.
28. Pasricha JS. Pulse Therapy in Pemphigus and Other Diseases. 2nd edn. New Delhi: Pulse therapy & Pemphigus Foundation. 2000.