SCIENCEFORECAST
Connecting Research to Drive Scientific Innovation
Published: 10 Apr, 2018

SF Journal of Gastroenterology

Short Interval Method for Regular Colonoscopy

*Kim H**

Department of Gastroenterology, Division of Internal Medicine, Leadheal Hospital, Seoul, Republic of Korea

Abstract

Conventional cap-fitting method,usually protruded 4mm-5mm from the end of the colonoscope, provides a continuous visual field of the lumen direction but has several disadvantages. The field of vision is affected by the cap. Feces or food remnant is easily impacted inside of the cap causing the blind situation. Finally, the extension of the forepart can cause laceration of the colonic mucosa, even perforation. The gist to solve this problem is to find out the appropriate interval between the end of a colonoscope and the end of a cap to minimize the protrusion of the cap while keeping an appropriate distance from the colonic mucosa. Long interval method, 4mm=<interval=<5mm, medium interval method, 1.5mm=<interval<4mm, and short interval method, 1mm=<interval<2.0mm, were tested. The *ex vivo* and *in vivo* experiments revealed that short interval method eliminates the disadvantages efficiently while maintaining the advantage.

Keywords: Cap-fitted colonoscopy; Cap; Colonoscopy; Short interval method; Short interval cap

Abbreviations

CFS: Cap-fiitted Colonoscopy; LIM: Long Interval Method; MIM: Medium Interval Method; SIM: Short Interval Method

Introduction

Usefulness of cap-fitted colonoscopy

Cap-fitted colonoscopy (CFC) is a simple method in which a transparent or nontransparent rubber cap is attached to the end of a colonoscope.CFC has been reported to be associated with reduced cecal intubation time, enhanced cecal intubation rate, and improved polyp detection rate [1-4]. The principle of CFC is keeping the end of the colonoscope a distance away from the colonic mucosa so that CFC can prevent red-out caused by attachment of colonic mucosa to the camera of a colonoscope. Consequently, CFC provides a continuous visual field of the lumen direction. Another important point of CFC is that least air-insufflation is possible during colonoscopy. With a cap,

Figure 1a: Conventional cap-fitted colonoscopy, long interval method (LIM). (a) LIM fits a cap protruding 4mm-5mm from the end of the colonoscope.

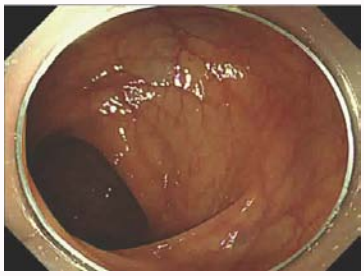

Figure 1b: The field of vision is inevitably affected by a cap in LIM.

OPEN ACCESS

Correspondence:
Hyunghun Kim, Department of Gastroenterology, Division of Internal Medicine, Leadheal Hospital, 10, Yeonseo-ro 10-gil, Eunpyeong-gu, Seoul, Republic of Korea.
Tel: *+82-2-382-7700*
Fax: *+82-2-302-7723*
E-mail: *relyonlord@gmail.com*
Received Date: *04 Mar 2018*
Accepted Date: *06 Apr 2018*
Published Date: *10 Apr 2018*

Citation: *Kim H. Short Interval Method for Regular Colonoscopy. SF J Gastroenterol. 2018; 1(1): 1006.*

Copyright *© 2018 Kim H. This is an open access article distributed under the Creative Commons Attribution License, which permits unrestricted use, distribution, and reproduction in any medium, provided the original work is properly cited.*

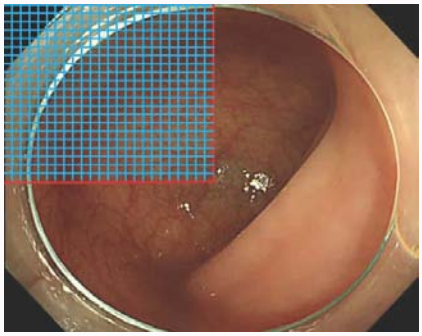

Figure 1c: Calculation by lattice shows approximately 25% of the field of vision is affected by a cap in this case.

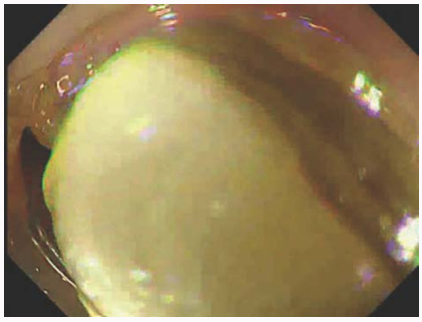

Figure 1d: Food remnant is impacted into inside the cap.

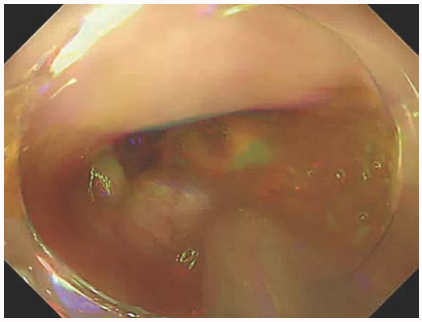

Figure 1e: Water injection (yellow dotted arrow) is essential to push out food remnant.

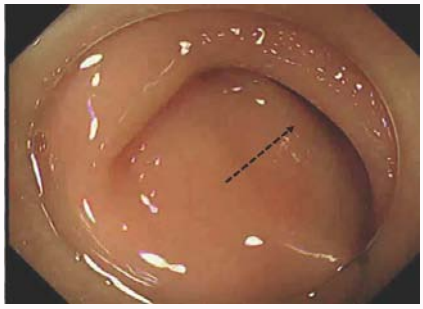

Figure 2: Presentation of long interval method-Slalom technique. A colonoscope slides into the space between folds (black dotted arrow) with the continuous visual field of lumen direction by the aid of a cap.

colonoscopists can anticipate to which the colonoscope should be advanced with much less air-insufflation than standard colonoscopy (SC), so CFC potentially enables a more comfortable examination with fast cecal intubation. A study revealed that the limited use of low

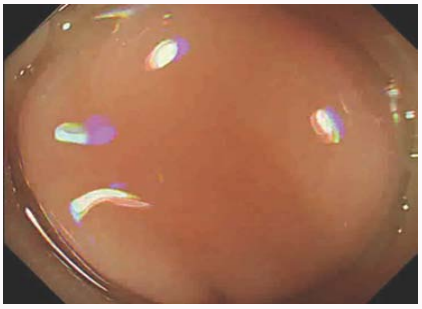

Figure 3a: Schematic presentation of the problem of long interval method-slalom technique. (a) The colonic fold is being pressed by the rim of a 4mm-5mm protruded cap so that the mucosa is being pushed into the inside of the cap.

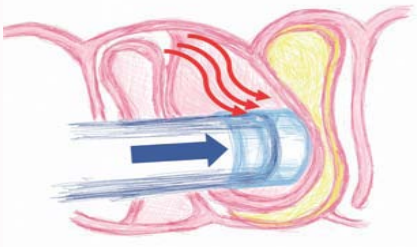

Figure 3b: The cap is pushing the front fold (pink color). Blue arrow indicated the direction of the advance of the colonoscope. Red arrows indicated the direction of the moving back of the front fold.

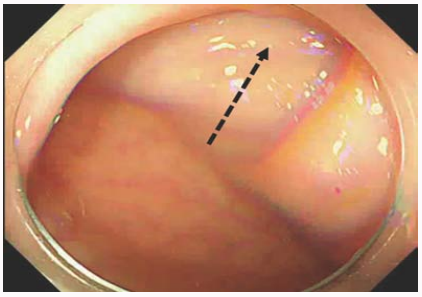

Figure 4a: Presentation of long interval method-Sliding technique. (a) Sliding technique is being performed toward 1 O'clock direction (black dotted arrow).

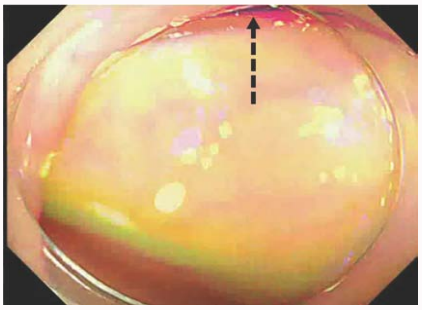

Figure 4b: The small space is noticed at the 12 O'clock direction (black dotted arrow).

air-insufflation in the rectum and sigmoid colon shortened the cecal intubation time and decreased post-procedural abdominal bloating [5]. For these reasons, CFC enables colonoscopists to achieve higher cecal intubation rate and shorter cecal intubation time. Two meta-analyses studies demonstrated that higher cecal intubation rate was achieved with CFC than SC [6,7]. Less-experienced colonoscopists

could gain more benefit from CFC than experts [4]. However, experts showed a shorter cecal intubation time with CFC also[8]. Furthermore, CFC has shown higher performance, especially in difficult situations, for example, prior abdominal operation, old age, and poor bowel preparation [9].

Disadvantages of cap fitted colonoscopy

Conventionally, CFC usually attaches a cap protruding about 4mm-5mm from the end of a colonoscope (Figure 1a): long interval method (LIM). LIM has several disadvantages although it has substantial advantages. First, the field of vision is affected by the cap (Figure 1b). This method inevitably narrows the field of vision. Colonoscopists should observe the colon through round opening of a cap compared to the wide visual field of SC. The transparent cap appears to solve this problem. However, the transparent cap is nearly opaque during the procedure, small scratches and water stain change the semi-transparent cap into nearly opaque. There is an insistence that the field of vision is not largely affected, so it is tolerable. However, approximately 25%-40% of the field of vision is affected by a cap (Figure 1c). Therefore, colonoscopists need to manipulate the end of a colonoscope to compensate this problem. Second, feces or food remnant can be easily impacted inside of the cap because LIM provides enough space, a cylinder with 12mm diameter and 4mm-5mm length. Colonoscopists face not only the clear vacant colon but also the colon filled with some feces and food remnants. When fecal or food remnant are impacted, colonoscopists cannot see anything because the camera of the colonoscope is covered by feces or food remnants (Figure 1d). In this situation, an assistant should inject water through a channel to resolve this problem; the repeated bothersome activity (Figure 1e). Third, the elongated forepart can cause laceration to the colonic mucosa. During colonoscopy, the end of a colonoscope frequently rotates to pass the curbed or twisted colon, so the end of a colonoscope easily touches and gives pressure to the colonic wall, especially during the sliding technique. These activities can result in colonic mucosal laceration and bleeding; the most serious consequence is a perforation. LIM increases the risk of mucosal laceration, bleeding and perforation because a turning radius is increased about 4mm-5mm. In a narrow space, 4mm-5 mm increase of a turning radius is a substantial disadvantage regarding mucosal laceration. Finally, performing two useful, advanced colonoscopy techniques, slalom technique and sliding technique, cannot be optimized with LIM. Slalom technique is one of insertion techniques which advances colonoscope between folds (Figure 2) like a slalom in Ski. The gist of slalom technique is sliding between folds without significant resistance. With LIM, however, the 4mm-5mm protruded rim of the cap occasionally presses folds although a colonoscope is moving laterally confronting the fold, consequently causes the mucosa of the fold to be pushed into the inside of the cap (Figure 3). Sliding technique is a method to advance a colonoscopenearly blindly for passing the seriously bent colon segments (Figure 4), so this technique has the risk of mucosal damage, bleeding, and perforation. With LIM, the possibility to acquire the continuous field of vision of lumen direction is increased during sliding technique, but sliding technique with LIM can increase the risk of mucosal laceration seriously and can cause substantial pain due to the 4mm-5mm extension of the forepart. Due to these disadvantages of LIM, CFC is not widely accepted as a standard method: rather regarded as a rescue method although CFC can provide an exceptional edge: the continuous visual field of the lumen direction. In this study, I tried to find out a solution to minimize the disadvantages of conventional CFC.

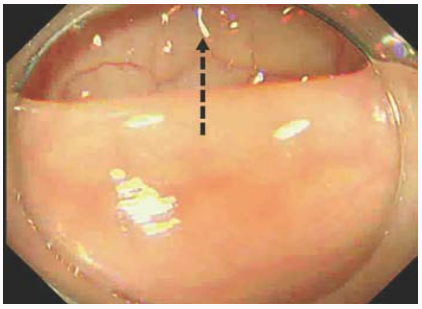

Figure 4c: The Next fold is identified behind the front fold (black dotted arrow).

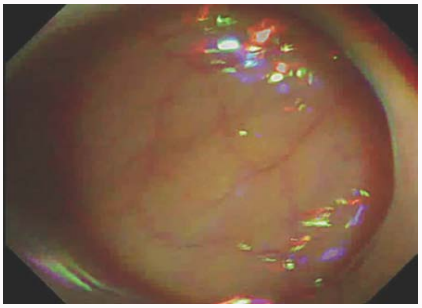

Figure 4d: The colonoscope is being successfully advanced overcoming the difficult situation with long interval method-sliding technique.

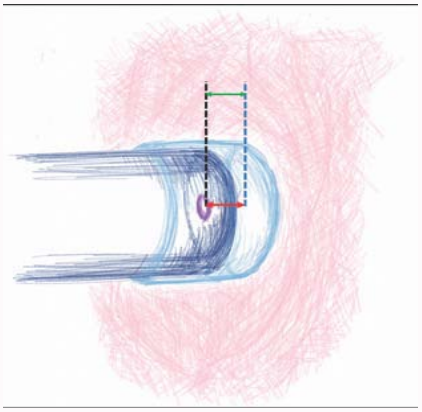

Figure 5: The principle of minimizing the disadvantage of cap-fitted colonoscopy (CFC). The interval between the black dotted line and the blue dotted line is the key point. The distance between the camera and the mucosa (red arrow) provide the advantage of CFC, and the protrusion length from the end of the colonoscope (green arrow) is responsible for the disadvantages. Therefore, finding out the appropriate interval between two dotted lines is the decisive factor for preventing disadvantages of CFC while maintaining its advantage.

Materials and Methods

Analyzing a factor affecting advantage and disadvantages of cap-fitted colonoscopy

The advantage of CFC is created by the interval, air-filled space, between the end of the cap and the end of the colonoscope (Figure 5). Therefore, the gist is finding out an appropriate interval between the end of the cap and the end of the scope which minimizes the protrusion of the cap from the end of a colonoscope while maintaining the air-filled space between the camera and the colonic mucosa to visualize



Figure 6a: The *ex vivo* experiment of the long interval method. (a) The interval between the end of a colonoscope and the end of a cap is about 4mm-5mm.



Figure 6b: The visual field reduction rate is about 40% with 5mm interval.



Figure 6c: The visual field reduction is about 25% with 4mm interval.

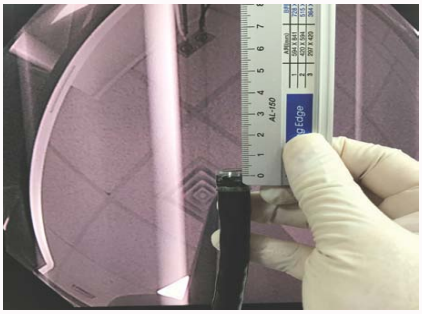

Figure 7a: The *ex vivo* experiment of medium interval method. (a) The interval between the end of a colonoscope and the end of a cap is about 2mm-3mm.

the lumen of direction continuously.

Ex vivo experiment

The CFC methods were divided into three groups depending on the interval between the end of the cap and the end of the colonoscope: 1) LIM: 4mm=<interval=<5mm, 2) Medium interval



Figure 7b: The visual field reduction rate is about 6% with 3mm interval.



Figure 7c: The visual field reduction is about 3% with 2mm interval.



Figure 8a: The *ex vivo* experiment of short interval method. (a) The interval between the end of a colonoscope and the end of a cap is about 1mm.

Figure 8b: The visual field is not affected by the cap.

method (MIM): 2mm=<interval<4mm, 3) Short interval method (SIM): 1mm=<interval<2mm. Three methods were tested to find out the optimal interval. The interval, the cap protrusion length, was measured by the same ruler in front of the colonoscopy screen for real-time observation of the visual field reduction. For measuring the proportion of the affected visual field, virtual squared paper, a lattice shape, was used after getting the photographs of LIM, MIM, and SIM, if there was the affected area by a cap. The proportion of affected

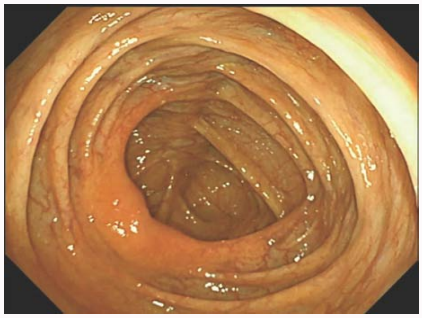

Figure 9: Field of vision of short interval method in *in vivo* study. Short interval method does not cause the reduction of the visualfield; the visual field is same as the standard colonoscopy.

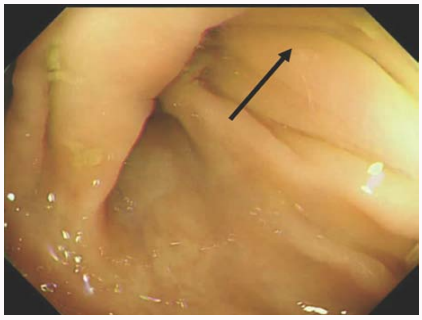

Figure 10a: Short interval method-Slalom technique. (a) Folds are overlapped, so the lumen is not directly visualized. A colonoscope is sliding perpendicular to the wrinkles of the fold (black arrow).

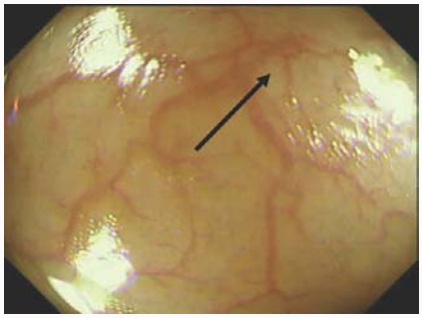

Figure 10b: A colonoscope is sliding confronting the fold following a black arrow. There is no red-out.

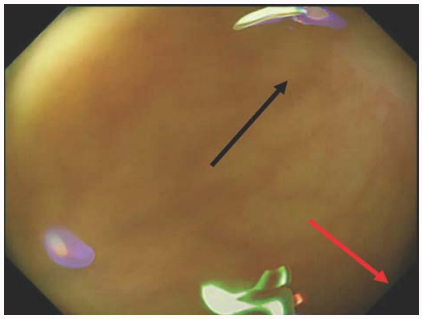

Figure 10c: While moving to the 1 O'clock side (black arrow), a small dark space is noticed at the 5 O'clock side (red arrow).

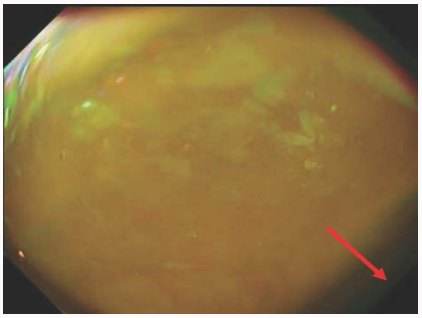

Figure 10d: The colonoscope is being advanced toward the 5 O'clock side, and the lumen is being noticed (red arrow).

Figure 10e: Lumen direction is being changed to the 3 O'clock side (red arrow), so the colonoscope is being advanced to the 3 O'clock side.

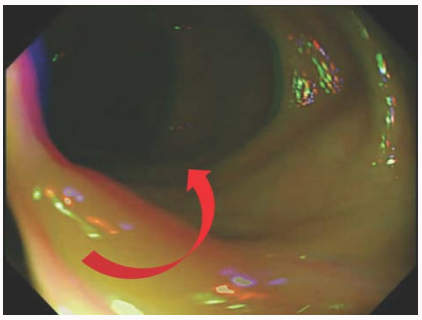

Figure 10f: Finally, the lumen is clearly identified when the colonoscope is being advanced following a red arrow.

visual field by a cap is regarded as visual field reduction rate.

In vivo experiment

The *in vivo* experiment was performed to find out an optimal cap-fitted method in regular colonoscopy environment. The Institutional review board of Kangnam Saint Peter's hospital endorsed this experiment, and written informed consents were acquired from patients. Each five patients were enrolled for LIM, MIM and SIM groups. Patients were connected to monitoring devices and placed in left lateral position. The patients underwent colonoscopy under procedural sedation and analgesia, with midazolam and pethidine. Oxygen was provided continuously through a nasal cannula. Intravenous medications were administered through an indwelling cannula. After adequate conscious sedation was achieved, the colonoscopy with LIM, MIM and SIM, was performed respectively. Checking points during *in vivo* experiment are as follows: 1) Maintenance of the continuous visual field direction, 2) The proportion ofthe visual field affected by the cap, 3) Performance of slalom technique, 4) Performance of sliding technique, 5) The presence of mucosal laceration and 6)Fecal or food remnant impaction.

Result

In *ex vivo* experiment using short interval method, LIM caused

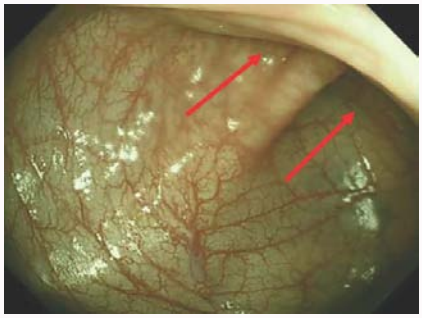

Figure 11a: Short interval method-sliding technique (SIM-sliding technique). (a) The direction of advancing a colonoscope is identified by pushing the colonoscope at both sides (red arrows).

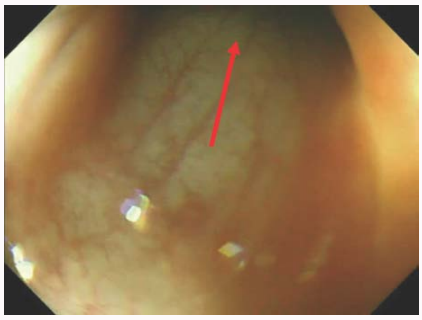

Figure 11b: SIM-sliding technique visualizes the space at the 2 O'clock side (red arrow).

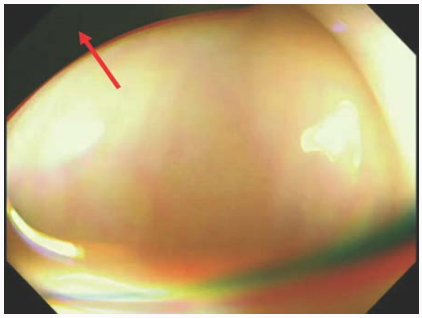

Figure 11c: Sliding the colonoscope toward the 2 O'clock side shows dark colon lumen at 11 O'clock side (red arrow).

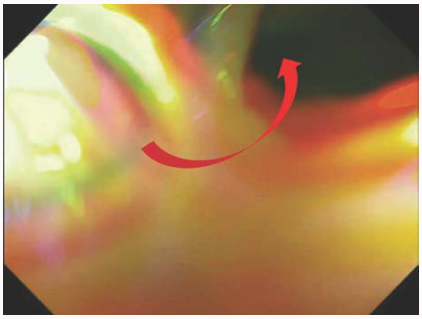

Figure 11d: The colonoscope is being smoothly advanced toward the lumen noticed at 11 O'clock side. However, the direction of a dark lumenis changed to the 1 O'clock side, so the colonoscope is being advanced following the direction of a red arrow.

approximately 25% to 40% visual field reduction depending on the interval, the protrusion length (Figure 6). MIM decreased the visual field about 3% to 6% (Figure 7). The field of vision was not affected by

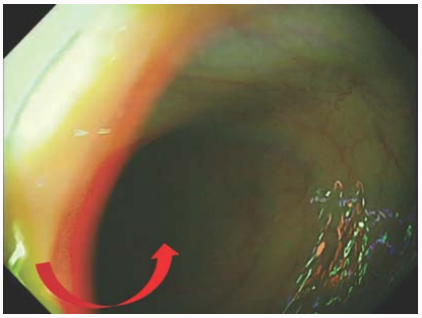

Figure 11e: Finally, the colonoscope reaches the lumen following a red arrow acquiring the continuous visual field of lumen direction.

a cap in SIM, same visual field to SC (Figure 8) [10,11].

During *In vivo* experiment, SIM, MIM, and LIM acquired the continuous visual field direction. The affected visual field was 0% in all SIM cases (Figure 9). However, MIN and LIM showed 3% to 6% and 25% to 40% visual field reduction rate depending on cap intervals. Slalom techniqueis easily performed in SIM (Figure 10). Sliding technique is smoothly performed in all SIM cases (Figure 11). MIM showed similar performance in slalom and sliding techniques. However, these techniques are relatively awkwardly performed in LIM. Moreover, sliding technique with LIM, one out of five cases, caused substantial pain and mucosal trauma (Figure 12). Fecal and food remnant were not impacted with SIM and MIM, but were impacted in two of LIM cases.

Discussion

This experiment showed SIM provided most appropriate interval for minimizing the disadvantages of CFC. The virtual square shape precisely presented the visual fields affected by a cap in three methods. SIM did not cause visual field reduction although MIM and LIM did. SIM and MIM did not provide a space for fecal impaction although LIM did have space for fecal or food remnant impaction. With SIM and MIM, performing slalom and sliding techniques are performed smoothly. However, LIM cased pain and mucosal trauma while performing sliding technique, and slalom technique was not performed smoothly and easily, it was quite awkward.

The limitation of this study is evident as bellows. The small number of people were enrolled, only 5 patients for each group. The limitation of this hospital, it is not an education institution, cannot but contribute this point. Second, this is one colonoscopists experience and opinion. Therefore, large scale study enrolling many cases and colonoscopists including novice and experts should be done to prove

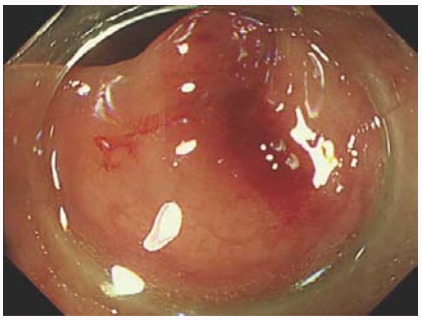

Figure 12: Mucosal trauma was noticed at which the long interval method-sliding technique was performed.

the efficacy and safety of SIM for regular colonoscopy.

The next step of this idea would be developing a short interval cap. Conventional caps can be used for SIM. However, there are two important problems. It can be difficult to fit a cap with 1mm-2mm interval easily and accurately. A conventional cap was originally designed to keep 4mm or 6mm interval so that a practitioner needs to adjust the interval to 1mm-2mm for SIM. Second, repeated cap fitting can damage covering of the colonoscope. The inner caliber of the forepart of a conventional cap is smaller than the caliber of the colonoscope. Therefore, a practitioner needs to push a cap with high pressure to make the colonoscope go through the inside of the cap for adjusting 1mm-2mm interval. To solve this problem, developing a short interval cap would be the most appropriate way.

References

1. Tada M, Inoue H, Yabata E, Okabe S, Endo M. Feasibility of the transparent cap-fitted colonoscope for screening and mucosal resection. Dis Colon Rectum. 1997; 40: 618-621.
2. Dafnis GM. Technical considerations and patient comfort in total colonoscopy with and without a transparent cap: initial experiences from a pilot study. Endoscopy. 2000; 32: 381-384.
3. Matsushita M, Hajiro K, Okazaki K, Takakuwa H, Tominaga M. Efficacy of total colonoscopy with a transparent cap in comparison with colonoscopy without the cap. Endoscopy. 1998; 30: 444-447.
4. Kondo S, Yamaji Y, Watabe H, et al. A randomized controlled trial evaluating the usefulness of a transparent hood attached to the tip of the colonoscope. Am J Gastroenterol. 2007; 102: 75-81.
5. Hsieh YH, Tseng KC, Lin HJ. Limited low-air insufflation is optimal for colonoscopy. Dig Dis Sci. 2012; 55: 2035-2042.
6. He Q, Li JD, An SL, et al. Cap-assisted colonoscopy versus conventional colonoscopy: systematic review and meta-analysis. Int J Colorectal Dis. 2012.
7. Westwood DA, Alexakis N, Connor SJ. Transparent cap-assisted colonoscopy versus standard adult colonoscopy: a systematic review and meta-analysis. Dis Colon Rectum. 2012; 55: 218-225.
8. Ng SC, Tsoi KK, Hirai HW, et al. The efficacy of cap-assisted colonoscopy in polyp detection and cecal intubation: a meta-analysis of randomized controlled trials. Am J Gastroenterol. 2012; 107: 1165-1173.
9. Kim HH, Park SJ, Park MI, Moon W, Kim SE. Transparent-cap-fitted colonoscopy shows higher performance with cecal intubation time in difficult cases. World J Gastroenterol. 2012; 18: 1953-1958.
10. Kim HH. Short Interval Method: Reasonable Choice for Regular Colonoscopy. Adv Res Gastroentero Hepatol. 2017; 7: 1-3.
11. Kim HH. Colonoscopy: Easy Cecal Intubation using Short Interval Method (Non-Blind Slalom & Sliding Techs). 2017.