SCIENCEFORECAST
Connecting Research to Drive Scientific Innovation

Research Article
Published: 31 May, 2019

SF Journal of Otolaryngology

Histopathology Evidence of Fungal Infection in Nasal Polyps

Ahmed MR[1], Abou-Halawa AS[2], Zittoon RF[3] and Makary EFY[4]*

[1]*Professor Otolaryngology, Faculty of Medicine, Suez Canal University, Ismailia, Egypt*

[2]*Assistant Professor of Otolaryngology, Faculty of Medicine, Suez Canal University, Ismailia, Egypt*

[3]*Lecturer of Otolaryngology, Faculty of Medicine, Suez Canal University, Ismailia, Egypt*

[4]*Lecturer of Histology, Faculty of Medicine, Suez Canal University, Ismailia, Egypt*

Abstract

Background: Nasal polyposis is a common chronic inflammatory disease of the nose and paranasal sinuses mucosa. Allergic Fungal Sinusitis (AFS) should be suspected in individuals with sinusitis and nasal polyposis. Tissue examination can provide accurate diagnosis of fungal infection by studying the histomorphology of fungus.

Aim of the Study: This study aims to identify presence of fungal infection in nasal polyps' studying specimen histopathology.

Patients & Methods: A prospective study was done on 96 patients with nasal polyposis subjected to functional endoscopic sinus surgery. The resected tissue was processed for light microscopy with hematoxylin and eosin stain to identify presence of fungus infection.

Results: Histopathological examination for nasal polyposis revealed that 24 patients (25%) had fungus infection when staining with Periodic Acid-Schiff (PAS) revealed dense esinophilic rounded fungal rod structures in the center of granuloma. In addition lamina propria shows basophilic aggregates with surrounding chronic inflammation with focal granulomatous inflammation.

Conclusion: Fungal infection could be associated with nasal polyps. It is better to investigate the presence of fungus in nasal polyps as antifungal therapy could be a treatment to prevent nasal polyposis from recurrence.

Keywords: Polyp; Nasal; Fungus; Investigation; Histopathology

OPEN ACCESS

Correspondence:
Mohamed Ahmed Rifaat, Professor Otolaryngology, Faculty of Medicine, Suez Canal University, Ismailia, Egypt.
Tel: *+201285043825*
Fax: *+20663415603*
E-mail: *m_rifaat@hotmail.com*

Received Date: *07 May 2019*
Accepted Date: *27 May 2019*
Published Date: *31 May 2019*

Citation: *Ahmed MR, Abou-Halawa AS, Zittoon RF, Makary EFY. Histopathology Evidence of Fungal Infection in Nasal Polyps. SF J Otolaryngol. 2019; 2(1): 1009.*

Copyright *© 2019 Ahmed MR. This is an open access article distributed under the Creative Commons Attribution License, which permits unrestricted use, distribution, and reproduction in any medium, provided the original work is properly cited.*

Introduction

Nasal polyposis is a chronic inflammatory disease of the nose and paranasal sinuses mucosa which is characterized by protrusion of oedematous polyps from the middle & superior meatus with demonstrated eosinophilic tissue infiltration and variety of pro-inflammatory cytokines and chemokines in nasal polyp epithelium and lamina propria [1].

Clinical as well as experimental studies indicate that nasal polyp formation and growth are activated and perpetuated by an integrated process of mucosal epithelium, lamina propria and inflammatory cells, which, in turn, may be initiated by both infectious and non-infectious inflammation [1].

Although surgery has been the preferred treatment for nasal polyposis for a long time, a change in the treatment strategy in recent years has greater use of medications, especially topical corticosteroids and antibiotics and anti-fungal [2].

Allergic Fungal Sinusitis (AFS) should be suspected in individuals with sinusitis and nasal polyposis based on the length the time symptoms are present before presentation and these patients usually have atopy and have had multiple sinus surgeries [3].

This entity is characterized by the presence of fungal forms invading into the sinonasal submucosal tissue with frequent angioinvasion and rapid intervention is necessary often requiring surgical and medical therapy [4].

Only tissue examination can provide accurate fungal infection by studying the histomorphology of fungus and associated tissue reaction to the fungus [5].

Infectious agents (including viruses, bacteria, or fungi) may be potential primary factors activating nasal epithelial cells proliferation and activation of fibroblasts leading to nasal polyp formation [6].

This study aims to identify presence of fungus in nasal polyps' studying specimen histopathology.

Subjects and Methods

A prospective study was done to evaluate presence of fungus in histopathological spacemen from nasal polyposis in the Suez Canal university hospital in the period from august 2016 to October 2018. 96 patients with nasal polyposis more than 2 years duration and subjected for endoscopic sinus surgery were included to our study while Cystic fibrosis, primary ciliary dyskinesia, the presence of lower airways obstruction symptoms, bronchial asthma, aspirin sensitivity were excluded from our study.

Study plan

All patients fulfilling the inclusion criteria were subjected to complete medical history, nasal endoscopic examination and CT paranasal sinus. Symptoms score system presence of nasal symptoms associated with nasal polyps (obstruction, anosmia, sneezing, rhinorrhea, and itching) zero for no symptoms, one for mild symptoms, two for moderate symptoms, and three for severe symptoms, so that the maximal global nasal symptom score was 15 according to Tsicopoulos *et al.* (2004) [7].

Nasal endoscopy: Nasal endoscopy was performed in a sitting position with a rigid endoscope 0°C and 30°C (Storz, Tuttlingen, Germany). Neither topical anesthesia nor decongestants were used scored according to Johansson *et al.* The grades of nasal polyps is classified in relation to fixed anatomical landmarks in four steps 0="no polyposis", 1="mild polyposis" ("small polyps not reaching the upper edge of the inferior turbinate"), 2="moderate polyposis" ("medium sized polyps reaching between the upper and lower edges of the inferior turbinate"), 3="severe polyposis" ("large polyps reaching below the lower edge of the inferior turbinate") [8]. Computerized Tomography (CT) of the nose and paranasal sinuses. Findings on CT scans were graded according to the Fokkens *et al.* [8] score. The mucosal abnormalities were graded as zero (no abnormality), one (partial opacification), or two (total opacification) of the frontal, maxillary, anterior ethmoid, posterior ethmoid and sphenoid sinus, bilaterally. The ostiomeatal complexes were scored bilaterally as zero (not occluded) or two (occluded). The maximal CT grading score is 24. All patients were subjected to Functional Endoscopic Sinus Surgery under general anesthesia in each case after obtaining informed consent. Standard surgical steps were applied in each case according to the extent of disease. Post operatively medications in form of nasal steroid drop, oral antihistamines and antibiotics with regular nasal toilet and debridement of nasal adhesions and crusting was done on each follow up visit. The resected nasal polyposis tissue was processed for light microscopy. Tissue specimens were fixed in 10% neutral buffered formalin, dehydrated in graded alcohol series, cleared in xylene and embedded in paraffin wax. Then 5μm thick paraffin sections were stained with Hematoxylin and Eosin stain and examined under the light microscope. Ten sections were examined for each patient, under the high power field (×40) [10]. They were also examined under Leica DM 1000 light microscope, in Center of Excellence in Molecular & Cellular Medicine, Faculty of Medicine, Suez Can University, Ismailia, Egypt. Assessment was performed by the examination of 10 sections from each patient, high power field (×400).

Table 1: showed basic Global Nasal Symptom Score among study population.

	GNSS
Obstruction	2.41±0.74
Anosmia	2.53±0.71
Sneezing	2.1±0.61
Rhinorrhea	2.5±0.9
Itching	1.7±0.79

GNSS= Global Nasal Symptom Score

Table 2: Showed both basic endoscopy score and the basic CT score among study population.

	Endoscopy score	CT score
Left Nasal Cavity	2.12±0.74	6.19±1.98
Right Nasal Cavity	2.6±0.11	6.9±3.1
Total	4.72±0.85	13.09±5.08

Statistical analysis

Data were collected processed using SPSS version 15 [SPSS Inc., Chicago, IL, USA]. Quantitative data expressed as means ± SD while qualitative data were expressed as numbers and percentages [%]. Student t test used to test the significance of difference for quantitative variables that follow normal distribution.

Ethical considerations

Written informed consent was obtained from all patients. The Local Ethical Committee approved the study.

Results

96 patients with nasal polyposis with mean age of 39.7±4.1 years and included 67 males (69.8%) and 29 females (30.2%) were subjected to FESS.

The preoperative Global Nasal Symptom Score domains including obstruction (2.41±0.74), anosmia (2.53±0.71), sneezing (2.1±0.61), rhinorrhea (2.5±0.9), itching (1.7±0.79) Table (1).

The preoperative endoscopy score for the left nasal cavity score (2.12±0.74) for the right nasal cavity (2.6± 0.11) and the total score (4.72±0.85) Table (2).

The CT score either for the left nasal cavity score (6.19±1.98) for the right nasal cavity (6.9±3.1) and the total score (13.09±5.08) Table (2).

All patients were subjected to FESS without major reported complications, 7 patients had adhesions and were treated with lysis and stent for 2 weeks.

Histopathological examination for nasal polyposis specimen revealed that 72 patients (75%) without any evidence for fungal infection as tissue revealed polypoid fragment lined with uniform non-keratinized stratified squamous epithelial lined with mucus secreting pseudostratified columnar epithelial covering and overlying edematous lamina propria with mild chronic inflammation with lymphoid aggregate (Figure 1,2 and 3).

While 24 patients (25%) had fungus infection as histopathological examination for nasal polyposis specimen revealed polypoid fragment lined with thickened uniform non-keratinized stratified squamous

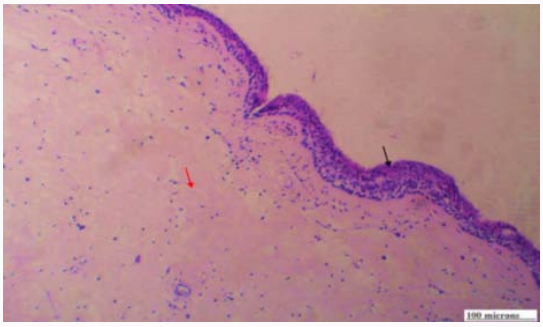

Figure 1: Sections examined from paraffin embedded tissue revealed polypoid fragment lined with uniform non- keratinized stratified squamous epithelial covering (Black arrow), overlying edematous lamina propria with mild chronic inflammation (Red arrow). There was no evidence of fungal infection (H&E, 10x).

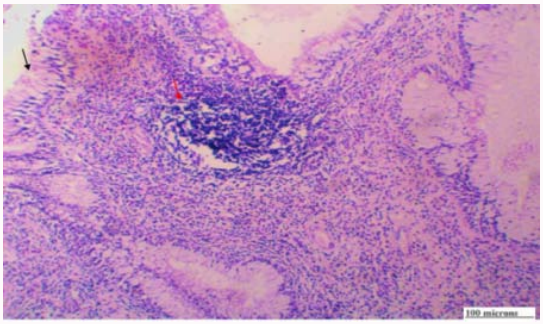

Figure 2: Sections examined from paraffin embedded tissue revealed polypoid fragment lined with mucus secreting pseudostratified columnar epithelial covering (Black arrow), overlying densely chronically inflamed lamina propria with lymphoid aggregate (Red arrow). There was no evidence of fungal infection (H&E, 10x).

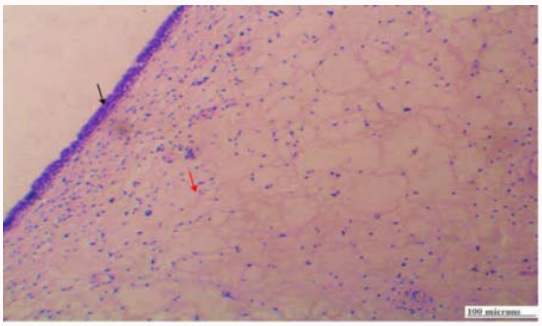

Figure 3: Sections examined from paraffin embedded tissue revealed polypoid fragment lined with uniform non- keratinized stratified squamous epithelial covering (Black arrow), overlying edematous lamina propria with mild chronic inflammation (Red arrow). There was no evidence of fungal infection (H&E, 10x).

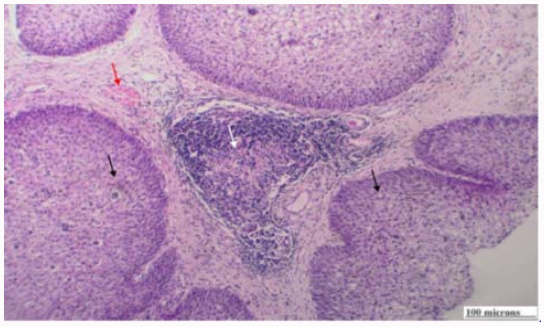

Figure 4: Sections examined from paraffin embedded tissue revealed polypoid fragment lined with thickened uniform non-keratinized stratified squamous epithelial covering (Black arrow), with dipping into underlying chronically inflamed lamina propria with congested blood vessels (Red arrow). There was focal granulomatous inflammation in the underlying lamina propria (White arrow) (H&E, 10x).

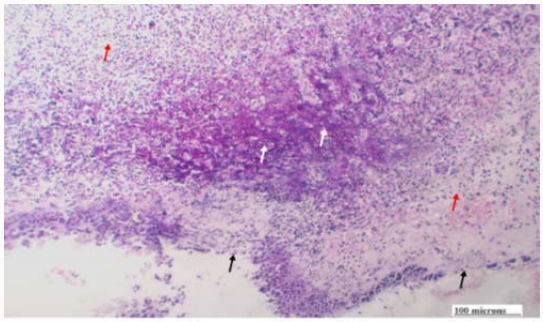

Figure 5: Sections examined from paraffin embedded tissue revealed polypoid fragment lined with uniform non- keratinized stratified squamous epithelial covering, with focal erosions (Black arrows). The underlying chronically inflamed lamina propria (Red arrows) show basophilic aggregates with surrounding chronic inflammation (White arrows) (H&E, 10x).

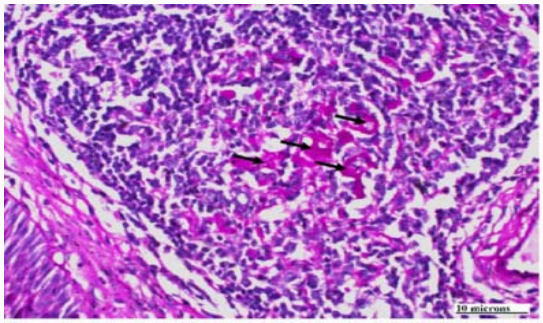

Figure 6: Staining with PAS revealed dense esinophilic rounded fungal structures (Black arrows) in the center of granuloma (PAS, 40x).

epithelial covering, with dipping into underlying chronically inflamed lamina propria with congested blood vessels and focal erosions, the underlying chronically inflamed lamina propria show basophilic aggregates with surrounding chronic inflammation with focal granulomatous inflammation in the underlying lamina propria when staining with PAS revealed dense esinophilic rounded fungal rod structures in the center of granuloma (Figure 4,5,6 and 7).

Discussion

Chronic Rhino Sinusitis (CRS) is a chronic inflammatory disease of the upper airways of which two major phenotypes exist, CRS without Nasal Polyps (CRSsNP) and CRS with Nasal Polyps (CRSwNP) [11].

The prevalence of CRSwNP is estimated to lie between 0.2 and 4%. Up to 15% of patients with asthma have nasal polyps and up to 45% of patients with nasal polyps have asthma [12].

Nasal polyps are a common problem with different etiologies and allergic fungal sinusitis which is a reaction to fungal antigens leads to nasal polyp's formation as Kuhn and Javer found specific IGE to fungal species was superior to total IGE [13].

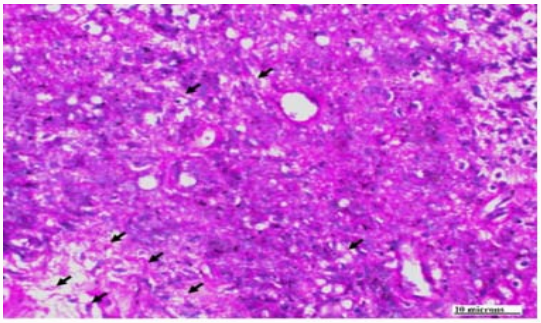

Figure 7: Staining with PAS revealed dense esinophilic fungal rod structures (Black arrows) in the lamina propria aggregate (PAS, 40x).

Bee-See *et al.* (2005) found that the incidence of AFS in adult Malaysian patients with refractory rhinosinusitis was 26.7%, they found fungus in secretions in only 5 patients (16.7%) and in nasal secretions and in surgical specimens in 11(36.7%) [14].

Ferguson reported that the recurrence of AFS following surgery is very high [15].

Allergic fungal sinusitis with nasal polyps previously considered rare, is now being reported with increasing frequency worldwide and should be considered in all patients with chronic sinusitis, allergic rhinitis, asthma, nasal polyposis [16].

Demonstration of fungal hyphae by direct microscopical examination and histopathology of tissue are the best for the diagnosis of fungal infection and this helps in identification of the etiologic agent in addition, Histopathology is important to distinguish the invasive from the non-invasive type [17,18].

In our study, fungus infection was 25% where Panda *et al.* found fungal ball in 60% from his study population [19].

Srivani *et al.* reported that Aspergillus species were the most common isolated fungi (17.3%) from the nasal polyps which are coinciding with other studies in contrast to the western studies where dematiaceous fungi are more common etiologic agents [20].

The pathogenesis of AFS is incompletely understood. Presumably, fungi become entrapped in the sinuses of allergic individuals with ostiomeatal complex obstruction, extremely thick mucus, or a mucociliary clearance disorder. The ensuing immune response exacerbates the disease [21].

More realistically, there may be a future role for topical antifungal drugs, which could hypothetically decrease antigen load. In vitro analysis of fungal susceptibilities indicates that the common AFS pathogens are sensitive to several antifungals available in irrigation solution [22].

We focused in our study for the histopathological assessment for on the presence of fungus infection but etiological factor could be investigated in another studies in addition utilization of antifungal therapy could be solution in some cases preventing the recurrence.

Conclusion

Fungal infection could be associated with nasal polyps. It is better to investigate the presence of fungus in nasal polyps as antifungal therapy could be a treatment for prevent nasal polyposis from recurrence.

References

1. Norlander T, Brönnegård M, Stierna P. polyps, infection, the relationship of nasal and inflammation. Am J Rhinol. 1999; 13: 349-355.
2. Nonaka M, Ogihara N, Fukumoto A, Sakanushi A, Pawankar R, Yagi T. Combined stimulation of nasal polyp fibroblasts with poly IC, interleukin 4, and tumor necrosis factor alpha potently induces production of thymus- and activation-regulated chemokine. Arch Otolaryngol Head Neck Surg. 2008; 134: 630-635.
3. Micheal RC, Micheal JS, Ashbee RH, Mattews MS. Mycological profile of fungal sinusitis: An audit of specimens over a 7 year period in a tertiary care hospital in Tamil Nadu. Indian Journal of Pathology and Microbiology. 2008; 51: 493-496.
4. Montone KT, Livosli VA, Feldman MD, Palmer J, Chiu AG, Lanza DC, et al. Fungal rhinosinusitis: a retrospective microbiologic and pathologic review of 400 patients at a single university medical center. Int J Otolaryngol. 2012; 2012: 684835.
5. Granvillae L, Chirala M, Cernoch P, Ostrowski M, Truong LD. Fungal sinusitis: Histologic spectrum and correlation with culture. Human Pathol. 2004; 35: 474-481.
6. Pawliczak R, Lewandowska-Polak A, Kowalski ML. Pathogenesis of nasal polyps: an update. Curr Allergy Asthma Rep. 2005; 5: 463-471.
7. Tsicopoulos A, Shimbara A, de Nadai P, Aldewachi O, Lamblin C, Lassalle P, et al. Involvement of IL-9 in the bronchial phenotype of patients with nasal polyposis. J Allergy Clin Immunol. 2004; 113: 462-469.
8. Johansson L, Akerlund A, Holmberg K, Melén I, Stierna P, Bende M. Evaluation of methods for endoscopic staging of nasal polyposis. Acta Otolaryngol. 2000; 120: 72-76.
9. Fokkens WJ, Lund VJ, Mullol J, Bachert C, Alobid I, Baroody F, *et al.* EPOS 2012: European position paper on rhinosinusitis and nasal polyps 2012. A summary for otorhinolaryngologists. Rhinology. 2012; 50: 1-12.
10. Bancroft JD. The haematoxylins: In Theory and Practice of Histological Techniques. 1990; 7: 107-111.
11. López-Chacón M, Mullol J, Pujols L. Clinical and biological markers of difficult-to-treat severe chronic rhinosinusitis. Curr Allergy Asthma Rep. 2015; 15: 19.
12. Dessouky O, Hopkins C. Surgical versus medical interventions in CRS and nasal polyps: comparative evidence between medical and surgical efficacy. Curr Allergy Asthma Rep. 2015; 15: 66.
13. Kuhn FA, Javer A. Allergic fungal sinusitis: a four-year follow-up. Am J Rhinol. 2000.
14. Goh BS, Balwant GS, Rose MI, Samad SA. Prevalence of allergic fungal sinusitis in refractory chronic rhinosinusitis in adult Malaysians. Otolaryngol Head Neck Surg. 2005; 133: 27-31.
15. Ferguson BJ. The diagnosis of allergic fungal sinusitis. In sinus surgery, endoscopic and microsscopic approaches. 2005.
16. Lanza DC, Dhong HJ, Tantilipikorn P, Tanaboee J, Nadel DM, Kennedy DW. Fungal and chronic rhinosinusitis from bench to clinical understanding. Ann Oto Rhinol Laryngol. 2006; 196: 27-34.
17. Chakraborti A, Sharma SC. Paranasal sinus mycoses. The Indian Journal of chest diseases and allied sciences. 2000; 42: 293-304.
18. Luong A, Marple B. The role of fungi in chronic rhinosinusitis. Otolaryngol Clin North Am. 2005; 38: 1203-1213.
19. Panda NK, Sharma SC, Chakrabarti A, Mann SB. Paranasal sinus mycoses in north India. Mycoses. 1998; 51: 493-496.
20. Srivani N, Madhuri S, Padma Malini K, Kumar OS, Nagamani. Incidence of fungal etiology in patients with nasal polyps. IAIM. 2016; 3: 19-25.

21. Sher TH, Schwartz HJ. Allergic aspergillus sinusitis with concurrent allergic bronchopulmonary Aspergillus: report of a case. J Allergy Clin lmmunol. 1988; 81: 844-846.

22. Bent JP, Kuhn FA. Antifungal activity against allergic fungal sinusitis organisms. Laryngoscope. 1996; 106: 1331-1334.