SCIENCEFORECAST
Connecting Research to Drive Scientific Innovation

Short Communication
Published: 31 Jul, 2020

SF Journal of Otolaryngology

A Pictorial Depiction of Neck Levels

Shakeel M[1]* and Ahmad Z[2]

[1]Department of Otolaryngology-Head and Neck Surgery, Aberdeen Royal Infirmary, Aberdeen, United Kingdom

[2]Department of Otolaryngology-Head and Neck Surgery, Counties Manukau Health, Auckland University, Auckland, New Zealand

Introduction

Neck lumps are a common presentation in the primary and secondary care medical facilities. Majority of these are cervical lymph nodes which are preferably described in relationship to neck levels. A clear understanding of the neck levels is essential in scientific communication between referring physicians. Neck levels nomenclature is also used when requesting investigations for example an ultrasound scan and fine needle aspiration cytology of the lump. These neck levels are numbered in Roman numerals I-VI. Sometimes the enlarged neck nodes could represent the metastatic cancer from the head and neck region [1].

Anatomically the neck levels are described as below [2]:

Level I: Sub-mental and sub-mandibular triangles (clinically between body of mandible and the hyoid bone).

Level II: From skull base to hyoid bone (corresponds to upper 1/3rd of the sternocleidomastoid muscle).

Level III: From hyoid bone to cricoid notch (corresponds to middle 1/3rd of the sternocleidomastoid muscle).

Level IV: From cricoid notch to clavicle (corresponds to lower 1/3rd of the sternocleidomastoid muscle).

Level V: Posterior triangle of the neck (The posterior triangle is bounded inferiorly by the clavicle, posteriorly by the anterior border of the trapezius muscle and anteriorly by the posterior border of the sternocleidomastoid muscle.)

Level VI: Anterior compartment of neck between the hyoid bone and supra-sternal notch.

When metastatic malignancy is suspected as the underlying cause for cervical lymphadenopathy then search for the primary tumour site should be carried out in a systematic fashion1 as detailed in Table 1. It is imperative that a detailed clinical history is taken in patients with suspected malignancy as described in Table 2. Detailed examination is followed by appropriate investigations (Table 3 and 4).

Table 1: Metastasis from the head and neck cancers tend to follow a pattern.

Lymph Node Group with Metastatic Cancer	Site of Primary Tumour
Pre-auricular (in front of the ear) and parotid nodes	Front half of the scalp and the skin of the upper part of the face
Post-auricular (behind the ear) and sub-occipital (the nape of the neck)	Back half of the scalp and the back part of the ear
Retropharynx (behind the throat, sitting in front of the spine)	The thyroid gland, nasopharynx and esophagus
Level I,II,III	Oral cavity
Level II,III,IV	Oropharynx, hypopharynx, larynx
Level V	Scalp, facial skin
Level VI	Thyroid, larynx, hypopharynx, esophagus

OPEN ACCESS

Correspondence:
Muhammad Shakeel, Consultant ENT/Thyroid Surgeon, Department of Otolaryngology-Head and Neck Surgery Aberdeen Royal infirmary, Aberdeen, AB252ZN, United Kingdom.
E-mail: *drshakeel@doctors.org.uk*
Received Date: *30 Jun 2020*
Accepted Date: *27 Jul 2020*
Published Date: *31 Jul 2020*

Citation: *Shakeel M and Ahmad Z. A Pictorial Depiction of Neck Levels. SF J Otolaryngol. 2020; 3(2): 1018.*

Copyright *© 2020 Shakeel M. This is an open access article distributed under the Creative Commons Attribution License, which permits unrestricted use, distribution, and reproduction in any medium, provided the original work is properly cited.*

Table 2: History to be taken in patients presenting with a neck lump.

Clinical presentation-History
Neck lump history -Onset -Duration -Progression -Pain -Discharge
Social history -Smoking -Alcohol -Betel nut chewing -Recent travel -Exposure to animals/bites/TB/HIV
Associated symptoms -Recent URTI -Cough/fever/sore throat -Dental problems -Otological complaints -Hoarseness -Odynophagia -Disphagia -Referred otalgia -Nasal obstruction/Bleeding -Haemoptysis -Haemetemesis -Weight loss -Night sweats -Malaise -Hx of previous skin lesion excision from head and neck region

Table 3: Clinical examination required in a patient presenting with a neck lump.

Clinical examination
Full Ear, Nose and Throat examination including pharyngolaryngoscopy
Examination of the neck lump focusing on -Number -Site -Size -Shape -Surface/skin -Tenderness -Consistency -Mobility -Bruit -Relationship to adjacent structures
Scalp and skin of head and neck
Cranial nerve examination
Systemic examination

Table 4: The investigations will be guided by the history and examination findings.

Investigating a neck lump
The investigations are guided by the clinical suspicion and may include -Blood tests Full blood count including Monospot test ESR CRP TFTs -USS of neck -FNAC -Chest x-ray -CT scan with or without contrast -MRI scan -MR angiogram -Barium swallow

Section 1: Level I of the neck

Level I neck lump: The Figure 1 and 2 show a large level I neck lump confirmed to be metastatic Squamous Cell Carcinoma (SCC). The primary tumour site could be in the oral cavity as demonstrated in Figure 3-6.

Figure 1: Large level I swelling.

Figure 2A: Left level I swelling-anterior view.

Figure 2B: Left level I swelling-lateral view.

Figure 3: Large tongue cancer (SCC).

Figure 4: Right tongue cancer.

Figure 5: Large floor of mouth cancer (SCC).

Figure 6: Right tongue and floor of mouth cancer.

Section 2: Level II of the neck

Level II neck lump: The Figure 7-10 in this section show metastatic nodes in level II of the neck-right and left side. The primary tumour was found in the tonsils or tongue base.

Figure 7A: Left neck level II node-anterior view.

Figure 7B: Left neck level II node-lateral view.

Figure 8A: Left neck level II metastatic node.

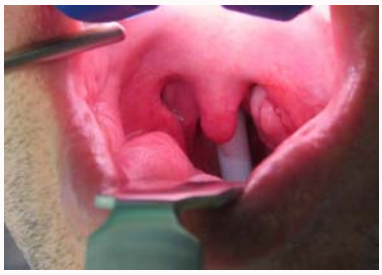

Figure 8B: Clinical photograph of oropharynx showing enlarged left tonsil secondary to squamous cell carcinoma. The tonsil felt firm on palpation.

Figure 8C: Excised left tonsil for histology.

Figure 8D: Right neck level II node.

Figure 9: Right tonsil malignancy invading the soft palate.

Figure 10: Right tonsil malignancy.

Section 3: Level III of the neck

Clinical photographs (Figure 11-14) in this section show metastatic nodes in level III of the neck-right and left. The primary tumour was found in oropharynx and hypopharynx on flexible pharyngolaryngoscopy.

Figure 11A: Left neck level II/III metastatic nodes.

Figure 11B: Left tonsil malignancy.

Figure 12: Right neck level III node.

Figure 13: Right neck level III metastatic node.

Figure 14: Right neck level III swelling.

Section 4: Level IV of the neck

The clinical photographs (Figure 15) in this section show level IV metastatic swelling.

Figure 15A: Right neck level IV swelling-anterior view

Figure 15B: Right neck level IV swelling-lateral view.

Section 5: Level V of the neck

The clinical photographs (Figure 16 and 17) in this section show metastatic nodes in level V.

Figure 16A: Right neck level V metastatic node involved in melanoma.

Figure 16B: Right neck level V metastatic node involved in melanoma.

Figure 16C: The patient had excision of melanoma from the right parietal region in the past.

Figure 17: Large metastatic nodes in the right posterior triangle of the neck (Level V).

Section 6: Level VI of the neck

The clinical photographs (Figure 18 and 19) here show a swelling in the anterior compartment of the neck-level VI.

Figure 18: Anterior neck level VI swelling.

Figure 19: Anterior neck level VI swelling.

Section 7: Neck nodes involving multiple levels of the neck (Figure 20-22).

Figure 20A: Large right neck metastatic nodes involving the level I, II, III and V-anterior view.

Figure 20B: Large right neck metastatic nodes involving the level I, II, III and V-lateral view.

Figure 21: Multiple metastatic neck nodes involving right neck level II, III, V and left neck level II and V.

Figure 22: Significantly enlarged abnormal nodes in the right neck level I, II, III, IV and V.

Acknowledgements

We are extremely grateful to all of the patients who allowed us to take their clinic photographs for education.

References

1. https://thancguide.org/cancer-types/neck/metastatic-lymph-nodes/anatomy/
2. https://medicine.uiowa.edu/iowaprotocols/selective-neck-dissection