SCIENCEFORECAST
Connecting Research to Drive Scientific Innovation

Research Article
Published: 09 Jul, 2020

SF Journal of Pulmonology and Respiration Care

Role of Ultrasonography in Diagnosis of Biliary Atresia with a Modified Triangular Cord Thickness and Gallbladder Classification

Nagesh M*

Consultant in Radio-Diagnosis & Fetal Medicine, Shanthi Nagar, Bangalore, Karnataka, India

Abstract

Purpose: To evaluate the diagnostic performance of Ultrasonography (US) in the identification and exclusion of biliary atresia with a modified triangular cord thickness metric together with a gallbladder classification scheme, as well as Hepatic Artery (HA) diameter and liver and spleen size, in a sample of jaundiced infants.

Materials and Methods: The ethics committee approved this study, and written informed parental consent was obtained. In 273 infants with conjugated hyperbilirubinemia (total bilirubin level 31.2 mmol/L, with direct bilirubin level. indirect bilirubin level), detailed abdominal US was performed to exclude biliary atresia. Biliary atresia was found in 129 infants and ruled out in 144. A modified triangular cord thickness was measured at the anterior branch of the right portal vein, and a gallbladder classification scheme was identified that incorporated the appearance of the gallbladder and a gallbladder length-to-width ratio of up to 5.2 when the lumen was visualized, as well as HA diameter and liver and spleen size. Reference standard diagnosis was based on results of one or more of the following: surgery, liver biopsy, cholangiography, and clinical follow-up. Area under the receiver operating characteristic curve (AUC) analysis, binary logistic regression analysis, Fisher exact test, and unpaired t-test were performed.

Results: Triangular cord thickness, HA diameter, ratio of gallbladder length to gallbladder width, liver size, and spleen size exhibited statistically significant differences (all P, 0.05) between the group with biliary atresia and the group with-out. AUCs of triangular cord thickness, ratio of gallbladder length to width, and HA diameters were 0.952, 0.844, and 0.838, respectively. Logistic regression analysis demonstrated that these three US parameters were significantly associated (all P, .05) with biliary atresia. The combination of triangular cord thickness and gallbladder classification could yield comparable AUCs (0.915 *vs* 0.933, *P*=.400) and a higher sensitivity (96.9% *vs* 92.2%), compared with triangular cord thickness alone.

Conclusion: By using the combination of modified triangular cord thickness and gallbladder classification scheme, most infants with biliary atresia could be identified.

Introduction

Biliary atresia is characterized by luminal obstruction of the extra-hepatic bile duct with a fibrous ductal remnant, which represents the obliterated ductal remnant in the porta hepatis at surgery [1,2]. If infants with biliary atresia are left untreated, progressive liver cirrhosis leads to death by 2 years of age [3]. Many other causes for neonatal jaundice exist that, unlike biliary atresia, can be relieved with medication or phototherapy. Hence, it is important to rule out biliary atresia among infants with jaundice.

Numerous ultrasonographic (US) features have been used in the diagnosis of biliary atresia [4-18]. Abnormalities in the shape and the wall of the gallbladder are useful US features in a biliary atresia diagnosis [7-9,11], but accurately identifying abnormal gallbladders remains a subjective task.

Further, advances in US imaging have shown that partially filled gallbladders can be reliably imaged among infants with conjugated hyperbilirubinemia, in cases such as gallbladders without visible lumen, gallbladders with incompletely filled lumen, and even absent gallbladders [7]. These situations complicate the identification of abnormal gallbladders.

OPEN ACCESS

Correspondence:
Nagesh Mruthyunjaya, Consultant in Radio-Diagnosis & Fetal Medicine, Shanthi Nagar, Bangalore, Karnataka, India.
Tel: *+91-9483047148*
E-mail: *dr.nageshmruthyunjaya@gmail.com*

Received Date: *07 Jun 2020*
Accepted Date: *03 Jul 2020*
Published Date: *09 Jul 2020*

Citation: *Nagesh M. Role of Ultrasonography in Diagnosis of Biliary Atresia with a Modified Triangular Cord Thickness and Gallbladder Classification. SF J Pulmonol Resp Care. 2020; 1(1): 1004.*

Copyright *© 2020 Nagesh M. This is an open access article distributed under the Creative Commons Attribution License, which permits unrestricted use, distribution, and reproduction in any medium, provided the original work is properly cited.*

The triangular cord sign, which is thought to reflect the obliterated fibrous ductal remnant, has been described as both sensitive and specific in the diagnosis of biliary atresia [4,5,10,11,18]. However, other authors have reported that the triangular cord sign is not sensitive [13,14,16,17,19-21]. Moreover, the visualization and measurement of triangular cord has varied among different studies [4,10-12,14,16,19,22], and in patients with early-stage biliary atresia, the triangular cord sign is obscured [23].

Other US features, such as enlargement of the Hepatic Artery (HA) diameter [15] and enlargement of the liver and spleen, are also helpful in biliary atresia diagnosis. However, the correct weighting among these features remains unknown. In addition, investigators in most published studies have used relatively small sample sizes, which potentially contribute to their varied results.

A better US method for differentiating patients with biliary atresia from those without could reduce or even eliminate the need for nuclear scintigraphy or biopsy.

The purpose of our study was to evaluate the diagnostic performance of US in the identification and exclusion of biliary atresia by using a modified triangular cord thickness metric together with a gallbladder classification scheme, as well as HA diameter and liver and spleen size, in a large sample of jaundiced infants.

Materials and Methods

Patients

This study was approved by our institutional Clinical Research Ethics Committee, and written informed parental consent was obtained.

Between August 2017 and November 2019, a total of 453 consecutive infants with conjugated hyperbiliru-binemia of unknown cause were prospectively evaluated. A conjugated hyperbilirubinemia was defined as a total bilirubin level of at least 31.2 mmol/L, with direct bilirubin level higher than that of indirect bilirubin level (the normal range of total bilirubin and direct bilirubin in our institution was 3.0-22.0 mmol/L and 0.5-7.0 mmol/L, respectively). Forty-three infants with a choledochal cyst and 29 infants older than 5 months were excluded. Another 108 infants lost during follow-up were also excluded. All infants underwent a series of investigations to establish the diagnosis. Among the 129 infants with biliary atresia, the diagnoses were confirmed by means of Kasai surgery and subsequent histologic examination (n=80), intraoperative cholangiography with laparoscopy (n=42), or liver biopsy (n=7). Among these 129 infants with biliary atresia, four infants had situs inversus. Another two had features of biliary atresia splenic malformation syndrome. Among the 144 infants without biliary atresia, cholescintigraphy showed that 108 of them had intestinal excretion. Their jaundice completely resolved during a follow-up period of 2 weeks to 12 months. Another 36 infants underwent intraoperative cholangiography with laparoscopy to confirm the presence of a patent bile duct. In eight of 36 infants, the jaundice did not resolve with medical therapy. Thus, diagnostic liver biopsies were performed (five had non-syndromic biliary hypoplasia, and three had progressive familial intra-hepatic cholestasis) (Figure 1).

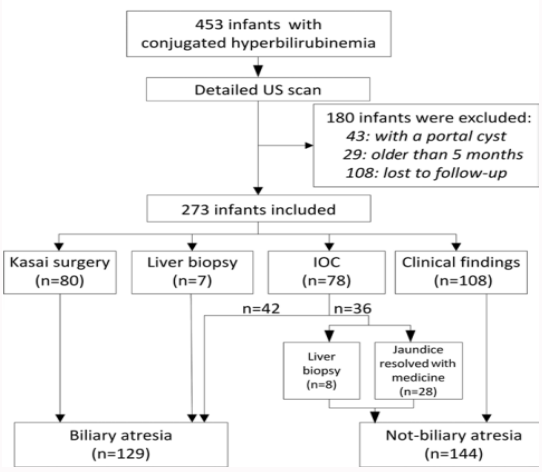

Figure 1: Flow diagram of the inclusion criteria for patients.
IOC = Inter-Operative Cholangiography

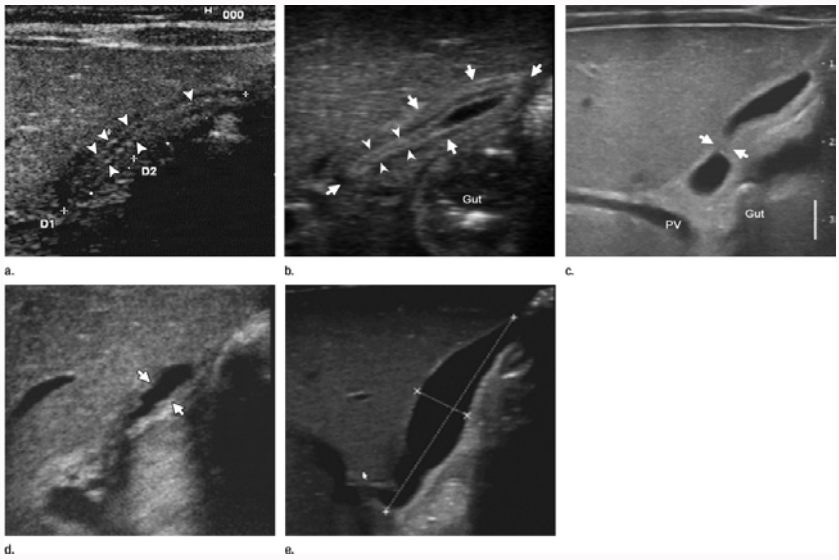

Figure 2: Images of varied types of gallbladder according to the gallbladder classification. (a) Type II gallbladder (calipers) with thickened wall and hyperechogenic mucosa. (b) Type II gallbladder (arrows) with a part of the mucosa (arrowheads) in close proximity. (c) Type II gallbladder with mucosa (arrows) in close proximity in the middle of the gallbladder in a infant without biliary atresia. (d) Type III gallbladder with a lumen (arrows) length of 1.2 cm in infant with biliary atresia and (e) Type IV gallbladder with a lumen length of 3.1 cm in a infant without biliary atresia.

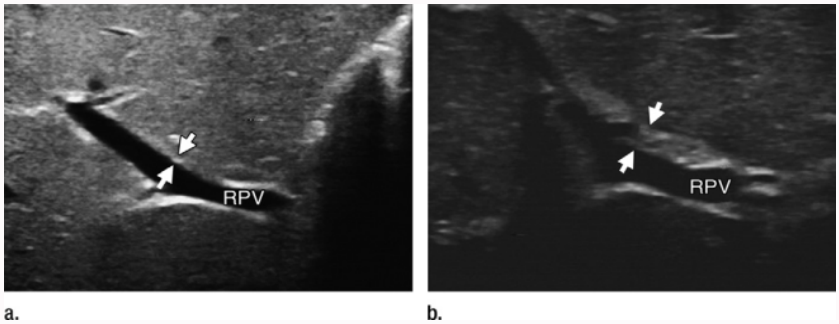

Figure 3: Longitudinal US images of fibrotic cord thickness at the anterior branch of the right PV (RPV). (a) Normal fibrotic cord (arrows) thickness of 1.2 mm in a infant with neonatal hepatitis. Hisjaundice completely resolved with medication and (b) Fibrotic cord (arrows) thickness of 2.5 mm in infant with biliary atresia.

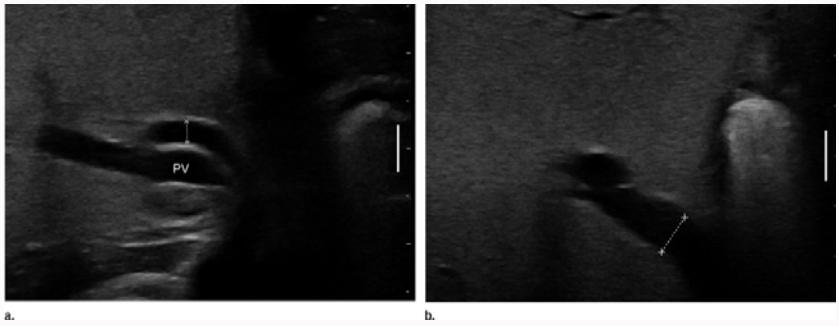

Figure 4: Measurement of HA and PV diameter. (a) The diameter of the HA lumen was measured and (b) The diameter of the PV lumen was measured at the level of main PV.

US imaging

All infants underwent a detailed abdominal US examination performed by one operator with more than 3 years of experience with pediatric US and who was blinded to the results of other investigations, such as cholescintigraphy and liver function testing. The US equipment used was a voluson E8 that incorporated a 3.5-MHz curvilinear transducer and a 12-MHz linear array transducer, Infants were not fed for at least 4 hours. First, high-frequency transducers (0.10MHz) were used to detect gallbladders.

Gallbladders were classified into four types (Figure 2): type I, gallbladder not detected; type II, gallbladder detected without lumen, but smooth and complete hyperechogenic mucosal lining was visualized and the wall was uniformly thickened, or the lumen was incompletely filled with smooth and complete hyperechogenic mucosal lining with the walls in part in close approximation [7]; type III, gallbladder detected with a fully filled lumen and lumen length equal or less than 1.5 cm without wall thickening; or type IV, gallbladder detected with fully filled lumen and lumen length more than 1.5 cm without wall thickening. If a gallbladder was detected, the section with maximum length was visualized to make classifications.

When the gallbladder wall was seen as a hypoechogenic layer between two hyperechogenic linings, it was considered thickened [9,24]. For type IV, the maximum lumen length and maximum width from inner wall to inner wall were measured, and the length-to-width ratio was calculated. We defined a positive gallbladder classification after retrospective analysis of our data as those types that could be used to predict biliary atresia (type I and type III and those with type IV with gallbladder length-to-width ratio of more than 5.2). A negative gallbladder classification was those types that could be used to predict absence of biliary atresia (type II and type IV gallbladders with length-to-width ratios of up to 5.2). After the gallbladder examination was finished, the patients were allowed to feed, and the triangular cord thickness and HA and Portal Vein (PV) diameters were assessed.

Triangular cord thickness was defined as the thickness of the echogenic anterior wall of the anterior branch of the right PV just distal to the right PV on a longitudinal image (Figure 3), without including the right HA, as modified from Lee et al [12]. Color Doppler flow imaging was used to help identify the right HA. Those less than 1 mm thick were arbitrarily assigned a thickness of 1 mm [12]. Only the thickness of the triangular cord was measured; the length was not recorded.

This triangular cord thickness, which we believed was formed by surrounding fibrosis caused by extra-hepatic biliary atresia, might be a more sensitive and earlier finding in infants with biliary atresia. Thus, we named this modified triangular cord thickness fibrotic cord thickness. The diameter of the HA and PV lumens was measured at the level of the main HA and main PV, respectively (Figure 4). Measurement was made from inner wall to inner wall and perpendicular to the wall. Fibrotic cord thickness, HA and PV diameter, and gallbladder length and width were measured at least twice, and the largest measurement was used for data analysis.

Finally, the oblique diameter of the right lobe of the liver and the splenic length were measured with curvilinear transducers (Figure 5).

Tests of reproducibility

Reproducibility and degree of agreement of identification and measurements for fibrotic cord thickness, gallbladder classification, HA diameter, and PV diameter were compared in 24 randomly selected infants (13 without biliary atresia and 11 with biliary atresia)

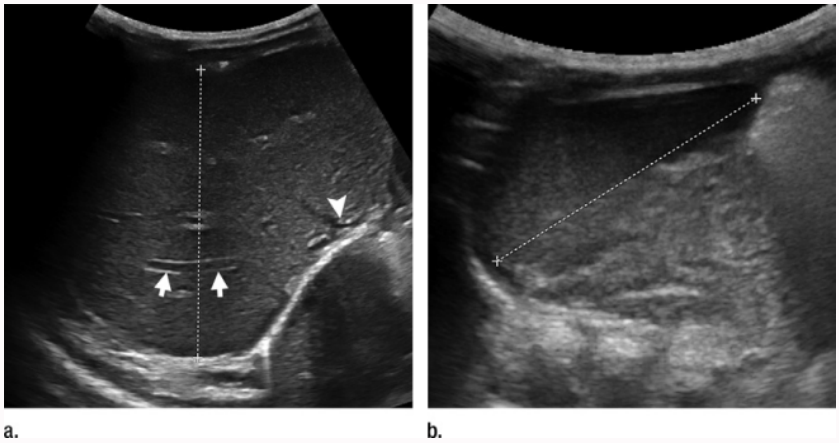

Figure 5: Measurement of the liver and spleen. (a) The oblique diameter of the right lobe of the liver and (b) Splenic length was measured (calipers) in the longitudinal coronal plane.

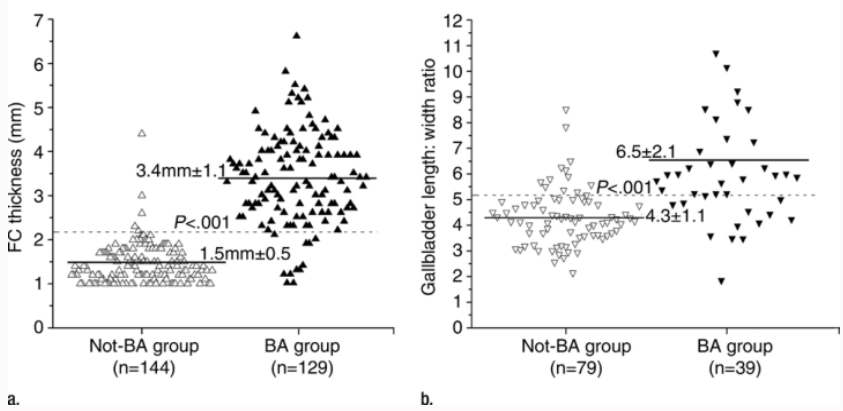

Figure 6: (a) Graph shows fibrotic cord thickness in patients with and those without Biliary Atresia (BA). Mean Fibrotic Cord (FC) thickness (3.4 mm 6 1.1 *vs* 1.5 mm 6 0.5, respectively, horizontal solid lines) was significantly thicker in infants with biliary atresia (P , 001), with an optimal cut-off value (dotted line) of 2.2 mm. (b) Graph shows gallbladder length-to-width ratio in 118 infants with gallbladder length of more than 1.5 cm. Mean gallbladder length-to-width ratio(6.5 6 2.1 *vs* 4.3 6 1.1, horizontal solid lines) was significantly higher in infants with biliary atresia (P, 001). Dotted line indicates the optimal cut-off value of 5.2.

each of these 24 infants was independently scanned by each operator. Three measurements of each parameter were obtained by each operator.

To determine inter-observer variability, the mean values of each parameter were compared between operators.

Image analysis of the gallbladder abnormality metric

Each type IV gallbladder was also reviewed in consensus by two radiologists both of whom were blinded to all infant data other than the maximum length section of the US gallbladder image, to determine if the shape or wall was normal or abnormal. A normal gallbladder was defined as one with globular or ovoid shape and without wall abnormalities. An abnormal gallbladder was defined as one with an abnormal wall and an irregularly compromised lumen [7,9,11,14]. The abnormal wall features included irregularity of the wall and thinner wall without mucosa.

Statistical analysis

The X^2 test was used to compare categorical variables. Continuous variables were first tested for normality by using a Kolmogorov-Smirnov test. An unpaired t test was used to compare normally distributed continuous variables.

Gallbladder classifications, fibrotic cord thickness, liver size, spleen size, PV and HA diameters, and clinical characteristics were compared between the group with biliary atresia and the group without.

Receiver operating characteristic curves were constructed to assess which US parameter (liver size, spleen size, PV diameter, HA diameter, fibrotic cord thickness, or gallbladder length-to-width ratio) yielded the most accurate biliary atresia diagnosis. The optimal cut-off points for the prediction of biliary atresia were identified from the highest Youden index (rounded to the nearest millimeter). The diagnostic performance of gallbladder length-to-width ratio and the gallbladder abnormality metric in determining biliary atresia among type IV gallbladders were compared. The sensitivity, specificity, positive predictive value, negative predictive value, and accuracy of statistically significant parameters in the diagnosis of biliary atresia were calculated. Additionally, binary logistic regression analysis with a stepwise method for selection of significant variables was performed to determine independent parameters for biliary atresia from the parameters that showed statistical significance in the univariate analysis.

To assess inter-observer error, intra-class correlation coefficients were used, and 95% confidence intervals were calculated. Intra-class correlation coefficients higher than 0.75 indicated excellent reliability.

Table 1: Patient characteristics at the time of USG examination.

Characteristics	Infants with biliary atresia	Infants without biliary atresia	*P* Value
Patient ratio	68+/-20	64+/-25	0.161
Male to female ratio	78	105	0.2
Total bilirubin level (umol/L)	183.5	174+/-93	0.34
Direct bilirubin (umol/L)	132+/-42	124+/-62	0.21
SGOT (U/L)	164=/-115	146+/-168	0.31
SGPT (U/L)	248+/-141	278+/-374	0.27

Table 2: Interobserver variation among infants.

Parameter	Intra-class Correlation Coefficient
Fibrotic cord thickness	0.94 (0.92, 0.96)
PV diameter	0.97 (0.96, 0.98)
HA diameter	0.95 (0.93, 0.96)
Gallbladder classification (type I–IV)	1.0
Gallbladder length-to-width ratio*	0.98 (0.96, 0.99)

Statistically significant differences were defined as those with P values less than 0.05, and analyses were performed with statistical software (SPSS).

Results

Clinical characteristics

Clinical characteristics between the group with biliary atresia and that without showed no significant difference in age, total bilirubin level, direct bilirubin level, alanine aminotransferase level, or aspartate aminotransferase level but did show a difference in patient sex (*P*=0.029) (Table 1).

Reproducibility of US imaging

The intra-class correlation coefficient for the three operators in the measurement of fibrotic cord thickness, PV diameter, and HA diameter ranged from 0.94 to 0.98, and the 95% confidence interval ranged from 0.71 to 0.99 (Table 2).

Gallbladders of type I in two patients, type II in three patients, type III in seven patients, and type IV in 12 patients were independently classified by each of the operators in exactly the same manner (Table 2).

Gallbladder classification

The number of infants with type I or type III gallbladders was higher in the biliary atresia group than in the group without, while the number of infants with type II or type IV gallbladders was smaller in the biliary atresia group than in the group without (P, 0.001, Table 3).

Fibrotic cord thickness

The fibrotic cord thickness in infants with biliary atresia (mean 6 standard deviation, 3.4 mm 61.1) was significantly higher than that in infants without biliary atresia (1.5 mm 60.5) (P, 0.001) (Table 4, Figure 6).

Other measurable US parameters

HA diameter in infants with biliary atresia (2.1 mm 60.4) was significantly higher than that in infants without biliary atresia (1.6 mm 60.3) (P, 0.001).

Liver size and spleen size in infants with biliary atresia were significantly higher than those in infants without biliary atresia,

Table 3: Gallbladder classifications in 273 infants with conjugated hyperbilirubinemia.

Gallbladder Classification	Infants with Biliary Atresia (n=129)	Infants without Biliary Atresia (n=144)	*P* Value
Type I	24 (18.6)	0	0.001
Type II	8 (6.2)	62 (43.0)	-
Type III	58 (45.0)	3 (2.1)	-
Type IV	39 (30.2)	79 (54.9)	-
Length-to-width ratio >. 5.2	30	12	0.001
Length-to-width ratio < 5.2	9	67	-
Abnormal findings of gallbladder assessment	33	14	-
Normal findings of gallbladder assessment	6	65	-
Positive total classification	112	15	-
Negative total classification	17	129	-

respectively (both P, 0.001). For infants with type IV gallbladders (n=118), the gallbladder length-to-width ratio was significantly smaller in the group without biliary atresia (4.3 +/- 1.1, n=39) than in the biliary atresia group (6.5, 62.1, n=79) (P, 0.001) (Figure 6). The PV diameter between the two groups was not significantly different (*P*=0.851) (Table 4).

AUC, binary logistic regression analysis of fibrotic cord thickness and gallbladder classification, and other US parameters

Areas under the receiver operating characteristic curve (AUCs) and the optimal cutoff for each measurable parameter in the identification of biliary atresia are listed in Table 4. The AUCs of fibrotic cord thickness, HA diameter, and type IV gallbladder length-to-width ratio were higher than 0.8. Therefore, type II and type IV gallbladders with a length-to-width ratio of up to 5.2 were regarded as negative gall-bladder classification, and type I, type III, and type IV gallbladders with a length-to-width ratio of more than 5.2 were regarded as positive gallbladder classification. In addition, the optimal cutoff value for fibrotic cord was determined as more than 2 mm.

Binary logistic regression analysis demonstrated that liver size and spleen size were not significantly associated with biliary atresia, whereas fibrotic cord thickness, HA diameter, and gallbladder classification were significantly associated (all P, 0.05) with biliary atresia (Table 5).

Diagnostic performance of US parameters

By using solely the optimal gallbladder length-to-width cutoff to diagnose biliary atresia in 118 infants with type IV gall bladders, the sensitivity, specificity, negative predictive value, positive predictive value, and accuracy were 76.9% (30 of 39 patients), 84.8% (67 of 79 patients), 88.2% (67 of 76 patients), 71.4% (30 of 42 patients), and 82.2% (97 of 118 patients), respectively. The gallbladder abnormality metric performed comparably, yielding 84.6% (33 of 39 patients), 82.3% (65 of 79 patients), 91.5% (65 of 71 patients), 70.2% (33 of 47 patients), and 83.0% (98 of 118 patients) (*P*=0.864), respectively (Tables 6 and 7).

Discordance between fibrotic cord thickness and gallbladder classification

Discordance between fibrotic cord thickness and gallbladder

Table 4: Diagnostic performance of different US parameters in 273 infants with conjugated hyperbilirubinemia.

Parameter	Infants with Biliary Atresia (n=129)	Infants without Biliary Atresia (n=144)	*P* Value	AUC*	Optimal Cut-off Value
Fibrotic cord thickness (mm)	3.4+/-1.1 (1-7.2)	1.5+/-0.5 (1-4.4)	<0.001	0.952	2.2
PV diameter (mm)	4.2+/-0.6 (2.7-5.8)	4.2+/-0.7 (2.5-7)	0.8	0.495	NA
HA diameter (mm)	2.1+/-0.4 (1-3.5)	1.6+/-0.3 (1-2.7)	0.001	0.838	1.9
Liver size (mm)	70.9+/-9 (50.0-93)	64.4+/-8.3 (39-90)	<0.001	0.699	67
Spleen size (mm)	64.2+/-13.9 (10.7-112)	56.5+/-11.1 (37-92.5)	<0.001	0.675	-
Type IV gallbladder					
No. of patients	39	79	-	-	-
Length (mm)	22+/-5.7 (15.1-46.0)	26.9+/-5.8 (15.2-41.0)	<0.001	0.276	NA
Width (mm)	3.8+/-1.4 (2.0-8.0)	6.6+/-2.3 (2.3-16.0)	<0.001	0.122	NA
Length-to-width ratio	6.5+/-2.1 (2.1-11.6)	4.3+/-1.1 (2.1-8.5)	<0.001	0.844	5.2
Gallbladder abnormality assessment	NA	NA	NA	0.834	NA

Table 5: Results of logistic regression B analysis for selected US parameters in the diagnosis of biliary atresia.

Parameter	Odds Ratio	95% Confidence Interval
Fibrotic cord	73.3	20.3, 264.9
Gallbladder classification	16.6	5.2, 53.1
HA	4.3	1.2, 15.1
Liver size	1.4	0.4, 4.8
Spleen size	0.6	0.2, 2.1

Table 6: Comparison of diagnostic Performance between the gallbladder classification scheme and the gallbladder abnormality assessment in the determination of biliary atresia among 118 infants with gallbladder length of more than 1.5 cm.

	Positive Predictive Value (%)	Negative Predictive Value (%)
Gallbladder classification scheme	84	76
Gallbladder abnormality assessment	82	84

classification was found in 13.6% (37 of 273) of the infants. Among 19 infants with fibrotic cord thicker than 2 mm and gallbladder classification negative, there was biliary atresia in 13 (including six of eight infants with biliary atresia with type II gallbladder) and no atresia in six. In contrast, among 18 infants with fibrotic cord of up to 2 mm and positive gallbladder classification, biliary atresia was diagnosed in six and excluded in 12.

Discussion

In this study, we demonstrated that a modified triangular cord thickness parameter has the highest diagnostic accuracy among all US parameters in the diagnosis of biliary atresia, followed by gallbladder classification. HA enlargement is only a supportive US feature in the diagnosis of biliary atresia, as is enlargement of the liver and spleen.

Adding HA enlargement to our modified triangular cord thickness and gallbladder classification did not improve the accuracy. These findings are important because infants with conjugated hyperbilirubinemia may receive accurate diagnoses and receive appropriate management in the early stage of their disease, potentially without the need for further nuclear scintigraphy.

Gallbladders are a critical point for identifying biliary atresia. An absent gallbladder or a gallbladder with length of up to 1.5 cm has a sensitivity ranging from 68% to 100% in the diagnosis of biliary atresia [6,7,9,14]. An abnormal gallbladder has a diagnostic accuracy of 91.9%-95.6% [9,14]. In our study, an absent gallbladder and a gallbladder up to 1.5 cm had a positive predictive value of 100% (24 of 24 patients) and 95.1% (58 of 61 patients), respectively, in the diagnosis of biliary atresia, which is comparable or superior to that in several previous studies [9,11,14,16,19].

Although other investigators [6,10,14] have mentioned that an absent gallbladder can also occur in those without biliary atresia, in our study, no false-negative cases were encountered. The main reason is likely that the newer US scanning technology with higher frequency probes in recent years likely prevents gallbladders without lumens from being missed. Kendrick et al., [13] also reported that the gallbladder in three of 20 babies with biliary atresia was "absent" with the ATL 3000 scanner but was seen when scanning with a different machine. Additionally, we found that 39 of 118 infants (33.0%) with gallbladder length of more than 1.5 cm were in the biliary atresia group, indicating that gallbladder length of more than 1.5 cm was ineffective when excluding biliary atresia [14].

Table 7: Diagnostic performance of fibrotic cord thickness, HA diameter & GB classification in determination of biliary atresia.

Parameter	Sensitivity (%)	Specificity (%)	Positive predictive value (%)	Negative predictive value (%)	Accuracy (%)	*P* Value
Fibrotic cord thickness >2mm	92	94	95	92	94	0.4
GB classification	86	90	88	88	88	0.5
HA >1.9mm	72	86	83	77	80	<0.001
Fibrotic cord thickness >2mm with GB classification	96	86	86	96	91	0.400
Fibrotic cord thickness >2mmwith HA >1.9mm	93	81	82	93	87	0.002
GB classification with HA >1.9mm	93	77	78	92	85	0.002
Fibrotic cord thickness >2mm with GB classification & HA >1.9mm	96	74	77	96	85	<0.001

To avoid subjectivity in evaluating gallbladders, we analyzed the ratio of gallbladder length to gallbladder width. The outcomes showed that the diagnostic performance was good. With an optimal cutoff value of 5.2, the diagnostic performance was comparable to that of the subjective grading of the gallbladder abnormality metric.

Few investigators have mentioned the importance of gallbladders without a lumen or gallbladders with an incompletely filled lumen in the diagnosis of biliary atresia. Some authors [11,22] considered that a gallbladder without a lumen was a sign of biliary atresia. However, Farrant et al., [7,9] found that only 18.3%-20.6% of empty gallbladders were in patients with biliary atresia. In our study, infants with type II gallbladders were more likely to not have biliary atresia, with a positive predictive value of 88.6% (62 of 70 patients). This finding indicated that an empty or incompletely filled gallbladder is associated with a patent bile duct at the porta hepatis. If the bile duct is completely obstructed at the porta hepatis, bile in the gallbladder does not flow out, even if the gallbladder contracts. Consequently, the gallbladder is fully filled and, over time, the gallbladder wall becomes irregular. Conversely, an empty gallbladder or an incompletely filled gallbladder with thickened walls indicates that the bile in the gall-bladder can come and go. In our clinical practice, the fully filled gallbladder of most infants without biliary atresia would become empty or incompletely filled, which was similar to gallbladders of type II after feeding for 1 to 3 hours.

Inspissated bile obstructing the bile duct might be one reason that the gall-bladders in infants without biliary atresia are not fully filled after fasting for at least 4 hours. Thus, we thought that infants with type II gallbladders were less likely to have biliary atresia. However, there were false-negative cases in our study (eight of 70 patients). For these cases, including fibrotic cord thickness measurement would potentially reduce misdiagnosis.

The triangular cord sign has a high specificity of 89%-100% [4,10-14,16-18,21,22] in the diagnosis of biliary atresia. However, the sensitivity has varied, ranging from 23.3% to 100% [4,10-14,16-18,21,22]. One difference among the various studies has been the location of the triangular cord sign.

The triangular cord sign was located in the vicinity of the PV [4] or right PV [12,15,16] or the bifurcation of the PV [10,11,14,25]. Another reason is that the standard for a positive triangular cord was different among the different studies. Lee et al., [12] considered that a positive triangular cord thickness, which could contain right HA, should be more than 4 mm. Kanegawa et al., [11] and Park et al., [6] mentioned that a thickness of 3 mm or more defined a positive triangular cord. Several other investigators did not mention how much thickness indicated a positive triangular cord finding [10,14,18].

Anatomically, triangular cord has been regarded as the fibrotic remnant of the obliterated cord with surrounding fibrosis in the periportal connective tissue [10], because the fibrotic remnants of the bile duct alone could not explain the whole triangular cord.

Choi et al., mentioned that a triangular cord might not be detected with US at an early stage in mild cases [4], and it may be more apparent as the disease develops. In addition, triangular cord can be re-identified in postoperative infants with biliary atresia with progressive jaundice because patients might continue to have ongoing fibrosis after a Kasai procedure [10,26]. Thus, a positive triangular cord sign with a thickness of at least 3-4 mm, as mentioned in previous studies, might be missed in many infants in early-stage biliary atresia.

In our study, fibrotic cord was defined as the thickness of the echogenic anterior wall of the anterior branch of the right PV just distal to the right PV, without including the right HA. Unlike those triangular cord signs that are located anterior to or near to the bifurcation of the PV, which might be influenced by periportal connective tissue, our fibrotic cord thickness is located at the beginning of the intra-hepatic bile duct and does not contain extra-hepatic duct remnants or right HA. Thus, our fibrotic cord might be more sensitive in terms of reflecting the surrounding fibrosis caused by extra-hepatic biliary atresia.

The fibrotic cord location we defined is similar to that of triangular cord defined by Lee et al., [12,16]. However, their optimal triangular cord thickness cutoff value was set by means of estimation. Our cutoff value was obtained by means of measurement. Although our optimal cutoff value is 2.2 mm, owing to the fact that US is not sufficiently sensitive to be able to measure 0.2 mm accurately, we suggest that a fibrotic cord thickness more than 2 mm should be considered a positive finding.

It should be emphasized that the fibrotic cord sign should not outweigh gallbladder classification in the diagnosis of biliary atresia [6]. Abnormal gallbladder classification might directly reflect an abnormality of the biliary system, especially when fibrotic cord thickness is negative.

Therefore, for infants with conjugated hyper-bilirubinemia, if either of the two US features is positive at US, biliary atresia should be suspected and further tests, such as inter-operative cholangiography with laparoscopy or biopsy, should be scheduled.

Our study had limitations. Although we conducted tests of reproducibility, most patients were scanned by one operator. This might have biased our results. Further, the thresholds for abnormality were set in the population from our single institution, and this might have led to overestimation of the diagnostic performance. Thus, our findings need to be validated in independent populations by other investigators.

In conclusion, with our modified triangular cord thickness parameter and more objective gallbladder classification, most infants with biliary atresia could be identified among infants with conjugated hyperbilirubinemia. However, it is still impractical to achieve 100% accuracy with US examination alone.

For those with negative US findings for both features, if the jaundice continues, further confirmatory investigation is needed to establish the cause of the conjugated hyperbilirubinemia.

References

1. Landing BH. Considerations of the pathogenesis of neonatal hepatitis, biliary atresia and choledochal cyst-the concept of infantile obstructive cholangiopathy. Prog Pediatr Surg. 1974; 6: 113-139.

2. Kasai M, Suzuki H, Ohashi E, Ohi R, ChibaT, Okamoto A. Technique and results of operative management of biliary atresia. World J Surg. 1978; 2: 571-579.

3. Hartley JL, Davenport M, Kelly DA. Biliary atresia. Lancet. 2009; 374: 1704-1713.

4. Choi SO, Park WH, Lee HJ, Woo SK. 'Tri-angular cord': a sonographic finding applicable in the diagnosis of biliary atresia. J Pediatr Surg. 1996; 31: 363-366.

5. Choi SO, Park WH, Lee HJ. Ultrasono-graphic "triangular cord": the most definitive finding for noninvasive diagnosis of extrahepatic biliary atresia. Eur J Pediatr Surg. 1998; 8: 12-16.

6. Park WH, Choi SO, Lee HJ. The ultrasonographic 'triangular cord' coupled with gallbladder images in the diagnostic prediction of biliary atresia from infantile intrahepatic cholestasis. J Pediatr Surg. 1999; 34: 1706-1710.

7. Farrant P, Meire HB, Mieli-Vergani G. Ultrasound features of the gall bladder in infants presenting with conjugated hyper-bilirubinaemia. Br J Radiol. 2000; 73: 1154-1158.

8. Tan Kendrick AP, Phua KB, Ooi BC, Subramaniam R, Tan CE, Goh AS. Making the diagnosis of biliary atresia using the triangular cord sign and gallbladder length. Pediatr Radiol. 2000; 30: 69-73.

9. Farrant P, Meire HB, Mieli-Vergani G. Improved diagnosis of extraheptic biliary atresia by high frequency ultrasound of the gall bladder. Br J Radiol. 2001; 74: 952-954.

10. Kotb MA, Kotb A, Sheba MF, El-Koofy NM, El-Karasky HM, Abdel-Khalik MK, et al. Evaluation of the triangular cord sign in the diagnosis of biliary atresia. Pediatrics. 2001; 108: 416-420.

11. Kanegawa K, Akasaka Y, Kitamura E, Nishiyama S, Muraji T, Nishijima E, et al. Sonographic diagnosis of biliary atresia in pediatric patients using the "triangular cord" sign versus gallbladder length and contraction. AJR Am J Roentgenol. 2003; 181: 1387-1390.

12. Lee HJ, Lee SM, Park WH, Choi SO. Objective criteria of triangular cord sign in biliary atresia on US scans. Radiology. 2003; 229: 395-400.

13. Tan Kendrick AP, Phua KB, Ooi BC, TanCE. Biliary atresia: making the diagnosis by the gallbladder ghost triad. Pediatr Radiol. 2003; 33: 311-315.

14. Humphrey TM, Stringer MD. Biliary atresia: US diagnosis. Radiology. 2007; 244: 845-851.

15. Kim WS, Cheon JE, Youn BJ, Yoo S, Kim WY, Kim I, et al. Hepatic arterial diameter measured with US: adjunct for US diagnosis of biliary atresia. Radiology. 2007; 245: 549-555.

16. Lee MS, Kim MJ, Lee MJ, et al. Biliary atresia: color Doppler US findings in neonates and infants. Radiology. 2009; 252: 282-289.

17. Mittal V, Saxena AK, Sodhi KS, Thapa BR, Rao KLN, Das A, et al. Role of abdominal sonography in the preoperative diagnosis of extrahepatic biliary atresia in infants younger than 90 days. AJR Am J Roentgenol. 2011; 196: W438-W445.

18. Kim MJ, Park YN, Han SJ, Yoon CS, Yoo HS, Hwang EH, et al. Biliary atresia in neonates and infants: triangular area of high signal intensity in the porta hepatis at T2-weighted MR cholangiography with US and histopathologic correlation. Radiology. 2000; 215: 395-401.

19. Li SX, Zhang Y, Sun M, Shi B, Xu Z, Hung Y, et al. Ultrasonic diagnosis of biliary atresia: a retrospective analysis of 20 patients. World J Gastroenterol. 2008; 14: 3579-3582.

20. Roquete ML, Ferreira AR, Fagundes ED, Castro LP, Silva RA, Penna FJ. Accuracy of echogenic periportal enlargement image in ultrasonographic exams and histopathology in differential diagnosis of biliary atresia. J Pediatr. 2008; 84: 331-336.

21. Imanieh MH, Dehghani SM, Bagheri MH, Emad V, Haghighat M, Zahmtkeshan M, et al. Triangular cord sign in detection of biliary atresia: Is it a valuable sign? Dig Dis Sci. 2010; 55: 172-175.

22. Park WH, Choi SO, Lee HJ, Kim SP, Zeon SK, Lee SL. A new diagnostic approach to biliary atresia with emphasis on the ultrasonographic triangular cord sign: comparison of ultrasonography, hepatobiliary scintigraphy, and liver needle biopsy in the evaluation of infantile cholestasis. J Pediatr Surg. 1997; 32: 1555-1559.

23. Saxena AK, Mittal V, Sodhi KS. Triangular cord sign in biliary atresia: Does it have prognostic and medicolegal significance. Radiology. 2012; 263: 621-622.

24. van Breda Vriesman AC, Engelbrecht MR, Smithuis RH, Puylaert JB. Diffuse gall-bladder wall thickening: differential diagnosis. AJR Am J Roentgenol. 2007; 188: 495-501.

25. Ryeom HK, Choe BH, Kim JY, Kwon S, Ko CW, Kim HM, et al. Biliary atresia: feasibility of mangafodipir trisodium-enhanced MR cholangiography for evaluation. Radiology. 2005; 235: 250-258.

26. Kotb MA, Sheba M, El Koofy N, Mansour S, El Karaksy HM, Dessouki NM, et al. Post-portoenterostomy triangular cord sign prognostic value in biliary atresia: a prospective study. Br J Radiol. 2005; 78: 884-887.