SCIENCEFORECAST
Connecting Research to Drive Scientific Innovation

Case Report
Published: 30 Mar, 2018

SF Journal of Urology

Malignant Paratesticular Mesothelioma: A Rare Entity

Moratalla Charcos LM[1], Pérez Martínez MA[1], Planelles Gómez J[1], Beamud Cortés M[1], De la Rosa Martínez FJ[1], Sánchez Sanchis MJ[1] and Vidal Moreno JF[2]*

[1]*Department of Urology, Hospital Universitario Doctor Peset, Valencia, Spain*

[2]*Head of Department of Urology, Hospital Universitario Doctor Peset, Valencia, Spain*

Abstract

Paratesticular mesothelioma is a rare entity, usually unilateral, painless and often associated hydrocele. Surgery can be curative in cases of localized disease. Paratesticular mesothelioma present a distinctive immunohistochemical pattern and local and lymph progression in 40% (distant metastases are less common). We present a malignant paratesticular mesothelioma case with progression after three years of the orchiectomy.

Keywords: Malignant mesothelioma; Testicular tumor; Tunica vaginalis; Hydrocele; Radical orchiectomy

Case Presentation

A 81-year-old man visit the Department of Urology in May 2013 due to painless enlargement of the left scrotum for 5 months, with no other symptoms. No medical or surgical history of interest other than osteoarthritis. On physical examination the left scrotum appeared to be edematous but there was no palpable mass. No left inguinal hernia was evident. No palpable lymph node was detected in the pelvic or inguinal areas. Ultrasonography found a large left hydrocele with multiple solid masses located around the testicle (Figure 1). The parenchyma and size of the right testis were normal. The blood test was normal: leukocytes and αFP, β-HCG and LDH levels were not elevated. The chest radiography was normal. We performed left radical inguinal orchiectomy enlarged scrotal covered under spinal anesthesia.

The pathology specimen (Figure 2) weight was 668g, measuring 23x9.5x8cm. There was a paratesticular cystic lesion of 14x9cm. Testis was displaced to the periphery of the tunica vaginalis. The cystic content lesions showed yellowish papillary serous areas (9x4 cm). Immunohistochemistry was positive for calretinin, CAM 5.2 (anti-cytokeratin), EMA (epithelial membrane antigen), Vimentin, CK7 and CK20, and was negative for CD15, CEA, CD30, αFP and CK5/6 (Figures 3-7). Pathological diagnosis was malignant paratesticular mesothelioma of the tunica vaginalis. There was no infiltration of the epididymis, spermatic cord, rete testis and testicular parenchyma, and also absence of vascular invasion, lymphatic or perineural with free resection margins. We didn't perform a CT scan because of the absence of infiltration of nearby and lymphatic structures. We consulted with medical oncologists, who suggested that no additional treatment was required. The patient had a follow-up with clinical examination every three months the first two years and every six months for the subsequent years. In April 2016 patient came to Emergency Department

Figure 1: Scrotal ultrasonographs show an increase in the size of the left scrotum, which was filled with multiple solid masses. The masses lie within the paratesticular region (tunica vaginalis).

OPEN ACCESS

Correspondence:
Moratalla Charcos LM, Department of Urology, Hospital Universitario Doctor Peset, Avda. Gaspar Aguilar, 90, Valencia, Spain.
Tel: *+34961622403*
E-mail: *luzmoratalla@comv.es*

Received Date: *28 Feb 2018*
Accepted Date: *28 Mar 2018*
Published Date: *30 Mar 2018*

Citation: *Moratalla Charcos LM, Pérez Martínez MA, Planelles Gómez J, Beamud Cortés M, De la Rosa Martínez FJ, Sánchez Sanchis MJ, et al. Malignant Paratesticular Mesothelioma: A Rare Entity. SF J Urol. 2018; 1(1): 1006.*

Copyright *© 2018 Moratalla Charcos LM. This is an open access article distributed under the Creative Commons Attribution License, which permits unrestricted use, distribution, and reproduction in any medium, provided the original work is properly cited.*

Figure 2: Macroscopic Pathological Anatomy. Hydrocele with lining of the vaginal tunic, smooth in almost all its extension. Area of 9 x 4 cm of papillary proliferation of different sizes.

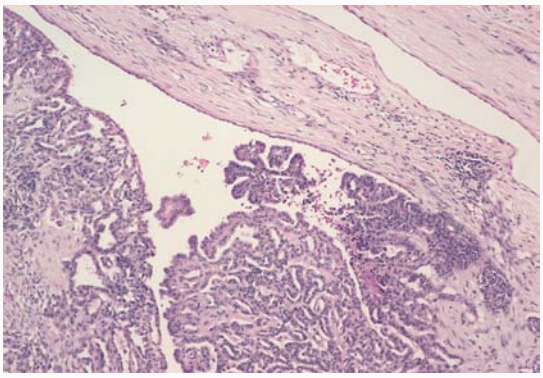

Figure 3: Papillary proliferation of the vaginal tunica with complex and branched papillae proliferating from the mesothelium (H & E stain, magnification 10x).

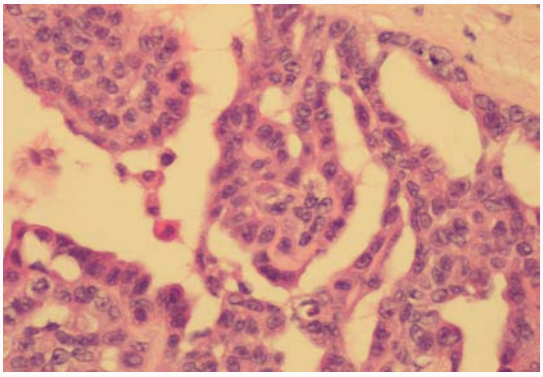

Figure 4: Proliferation of epithelial cells with cytologic atypia, forming tubules, papillae and solid areas. Broad eosinophilic cytoplasm cells with epithelial habit, with nuclei with irregular nuclear membrane, pleomorphic, prominent nuclei. Occasional Mitosis (H & E stain, magnification 40x).

with left renal colic clinic. The abdominal radiography was normal (urolithiasis absence). In August contrast-enhanced CT imaging (Figure 8) showed a hypodense left para-aortic retroperitoneal lesion (31 x 26 x 35 mm), located below the renal artery exit, which does not seem to depend on any adjacent structure, with 24 HU attenuation coefficient. Patient was symptomatic. In June 2017 contrast-enhanced CT imaging (Figure 9) showed retroperitoneal mass growth (54mm) which caused left renal vein thrombosis. Dilation of the pyelocalicial system was likely due to ureteral entrapment. The mass contacted the left psoas muscle without a fatty plane of separation with it or with

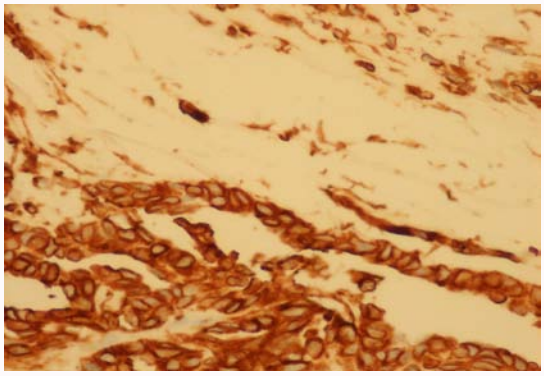

Figure 5: Immunohistochemically positive vimentin staining in the malignant mesothelial cells (magnification 20x).

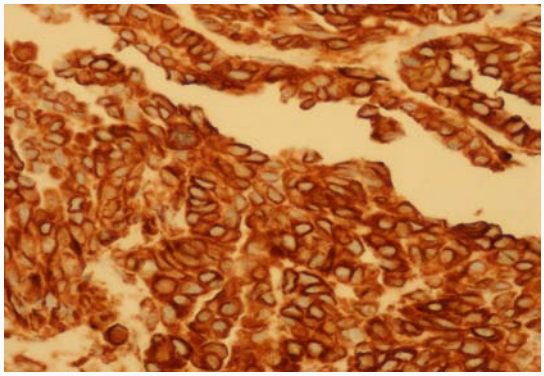

Figure 6: Immunohistochemically positive CAM5.2 staining in the malignant mesothelial cells (magnification 40x).

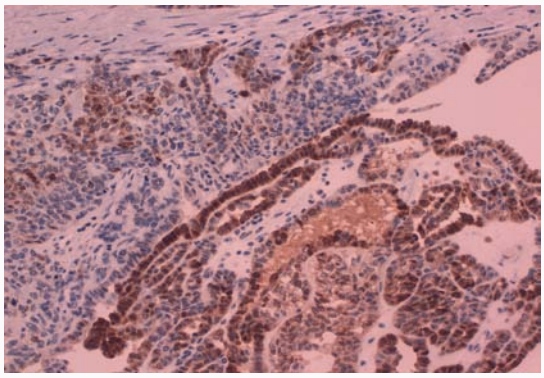

Figure 7: Immunohistochemically positive calretinin staining in the malignant mesothelial cells (magnification 100x).

aorta. Right lower lobe nodule lung (Figure 10) with spiculated edges, of 3cm with satellite nodules in the same lobe and one in left lobe in relation to possible metastasis. Patient received palliative care and died few months later, at 85 years old.

Discussion

Mesotheliomas are tumors formed from the coelomic serous cavities (pleura, pericardium, peritoneum or tunica vaginalis). Approximately 68-85% of malignant mesotheliomas originate from the pleura, and 9-24% arises from the peritoneum [1]. A mesothelioma, within the tunica vaginalis of the paratesticular region is rare but often fatal malignancy of the male genitalia [2]. The first case of malignant mesothelioma at the tunica vaginalis of

Figure 8: Abdominal computed tomography shows hypodense left para-aortic retroperitoneal lesion (31 x 26 x 35 mm), 24 HU, located below the renal artery exit. Not depend on any adjacent structure.

Figure 9: Abdominal computed tomography shows retroperitoneal mass growth (54mm) which causes left renal vein thrombosis. Dilation of the pyelocalicial system due to ureteral entrapment. The mass contacts the left psoas muscle without a fatty plane of separation with it or with aorta.

testis was described by Barbera and Rubino in 1957. Paratesticular mesothelioma originating in the tunica vaginalis represents less than 5% of all mesothelioma [3]. To date, approximately 250 cases of malignant mesothelioma have been reported worldwide [4].

On the other hand, paratesticular tumor represent only 7-10% of the scrotal masses and within them, the most frequent are those originating in the spermatic cord (75- 90%), followed by metastatic (10%) and finally those formed at the expense of epididymis and scrotal tunics [5].

In patients with malignant mesothelioma at the tunica vaginalis of the testis, more than two-thirds of the cases were patients older than 45 years old, with a median age of 60 years old [6], although malignant mesothelioma has been reported in teenagers [7]. The only risk factor found is exposure to asbestos, but the disease may also occur in the absence of any obvious risk factors [8].

Malignant mesotheliomas manifest as painless scrotal size increases, often with reactive hydrocele. Often infiltration testis, epididymis, cord, skin of the penis and scrotum. A clinical differential diagnosis consists of a hydrocele, testicular tumors, inflammatory processes (epididymitis), inguinal hernia. Imaging studies can help

Figure 10: In abdominal computed tomography we can see a 3cm right pulmonary nodule (Figure 10), in lower lobe, with spiculated edges.

identify tunical surface irregularities, soft tissue masses and fluid accumulation.

With regard to histology, the nodules consist of mesotheliomas gray, with morphological variety: nuclear polymorphism, mitotic activity and areas of stromal invasion. A wide spectrum of differentiation from well-differentiated (tubulopapillary structure, atypical mesothelial cells) to poorly-differentiated (solid lesions, epithelioid cells with necrosis). They have an exophytic papillary growth [9]. Sometimes Psammoma bodies are observed in the papillary areas of the tumor. Immunohistochemical staining show positivity for mesothelioma-related markers: calretinin, WT-1, thrombomodulin, CKs 5/6), vimentin, CAM 5.2 [10], cytokeratin and CK 7 [11]. On the other hand, are negative for adenocarcinoma-related markers (CEA, Leu M1, B72.3, Ber EP4). EMA remain conflicting contradictory. In our case, EMA was positive, and CK7/CK20 were too positive (markers useful in characterizing metastasis of unknown origin).

Literature describes about 15% [12] of paratesticular mesothelioma associated lymphatic inguinal invasion or abdominal structures, giving metastasis, less frequently, lung, liver and pleura. In our patient, metastases appeared 3 years later.

Mesotheliomas are difficult to manage and no clear guidelines exist for management. Surgery has been suggested (radical orchiectomy). Lymph node dissection can be considered in the case of lymph node enlargement. Chemotherapy and radiotherapy show only minor effectiveness. Cisplatin and pemetrexed can be used for mesotheliomas, while radiotherapy may be helpful in preventing disease recurrence [13].

Our patient didn't receive radiotherapy or chemotherapy because it was an early stage and showed no sign of metastasis at the time of the diagnosis. Regular follow-up plan is essential for the early diagnosis of metastasis. In our case, when disease progress was detected, the patient was not a candidate for chemotherapy.

The mortality rate has been reported to be 53% over a mean follow-up time of two years [14].

The overall prognosis is poor, despite radical surgery and systemic therapy [15] with a median survival of 23 months, with 14 months in patients with local recurrence.

Conclusion

Paratesticular malignant mesothelioma is a rare tumor, which should be considered despite the absence of asbestos exposure or previous trauma. Clinically indolent, except for cases of reactive hydrocele. The ultrasound findings will help us in its diagnosis. Radical orchiectomy is the treatment of choice. It has poor prognosis.

References

1. Zhang N, Fu N, Peng S, Luo X. Malignant mesothelioma of the tunica vaginalis testis: a case report and literature review. Mol Clin Oncol. 2017; 7: 1053-1056.
2. Guney N, Basaran M, Karayigit E, Müslümanoglu A, Guney S, et al. Malignant mesothelioma of the tunica vaginalis testis: a case report and review of the literature. Med Oncol. 2007; 24: 449-452.
3. Goel A, Agrawal A, Gupta R, Hari S, Dey AB. Malignant mesotelioma of the túnica vaginalis of the testis without exposure to asbestos. Cases J. 2008; 1: 310.
4. Mrinakova B, Kajo K, Ondrusova M, Simo J, Ondrus D. Malignant mesothelioma of the tunica vaginalis testis. A clinicopathologic analysis of two cases with a review of the literature. Klin Onkol. 2016; 29: 369-374.
5. Uría J, Escalera C, Sánchez J, Areal J, Sanfeliú F, et al. Mesotelioma maligno de túnica vaginal. Actas Urol Esp. 2000; 24: 757-760.
6. Chen JL, Hsu YH. Malignant mesotelioma of the túnica vaginalis testis: a case report and literatura review. Kaohsiung J Med Sci. 2009; 25: 77–78.
7. Ko KWS, Tse KS, Shek KW, Hau MN, Ting SH. Well-differentiated papillary mesothelioma of tunica vaginalis testis of unknown malignantpotencial: sonographic appearance. J Clin Ultrasound. 2017; 1-4.
8. Akin Y, Bassorgun I, Basara I, Yucel S. Malignant mesothelioma of tunica vaginalis: an extremely rare case presenting without risk factors. Singapore Med J. 2015; 56: e53-e55.
9. Churg A. Paratesticular mesothelial proliferations. Semin Diagn Pathol. 2003; 20: 272-278.
10. Van Cauwelaert R, Ruiz-Tagle D, Meneses M, Carrasco AM, Aguirre C. Tumores no germinales insulares del testículo: tres casos clínicos. Actas Urol Esp. 2007; 30: 923-927.
11. Amin MB. Selected other problematic testicular and paratesticular lesions: rete testis neoplasms and pseudotumors, mesothelial lesions and secondary tumors. Mod Pathol. 2005; 18: 131-145.
12. Campbell-Walsh Urología. Ed. Panamericana. 8ª edición. 2004; 3186-3187.
13. Ceresili GL, Zucali PA, Favaretto AG, Grossi F, Bidoli P, et al. Phase II study of permetrexed plus carboplatin in malignant pleural mesotelioma. J Clin Oncol. 2006; 24: 1443-1448.
14. Gürdal M, Erol A. Malignant mesotelioma of túnica vaginalis testis associated with long-lasting hidrocele: could hidrocele be an etiological factor?. Int Urol Nephrol. 2001; 32: 687-689.
15. Brimo F, Illei PB, Epstein JI. Mesothelioma of the tunica vaginalis: a series of eight cases with uncertain malignant potential. Mod Pathol. 2010; 23: 1165-1172.